



Unit : Intestinal stasis in cattle

Lesson : 5

Management of ileus

Dr. G. Vijayakumar, M.V.Sc., Ph.D., PGDECM

Professor

Veterinary University Peripheral Hospital

Madhavaram Milk Colony

Chennai-600 051

Tamil Nadu Veterinary and Animal Sciences University

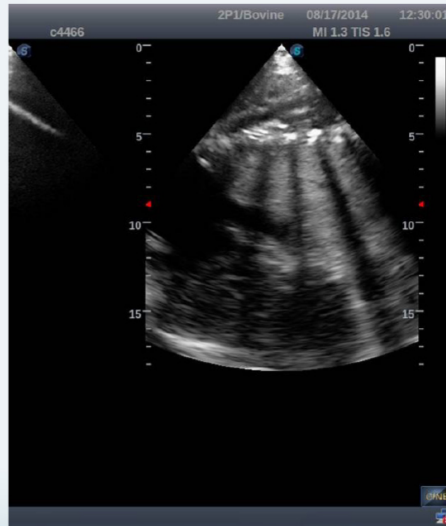
Ultrasonography of pregnancy

- Recognition - pregnancy and the fetal viability during imaging of the abdominal / pelvic organs

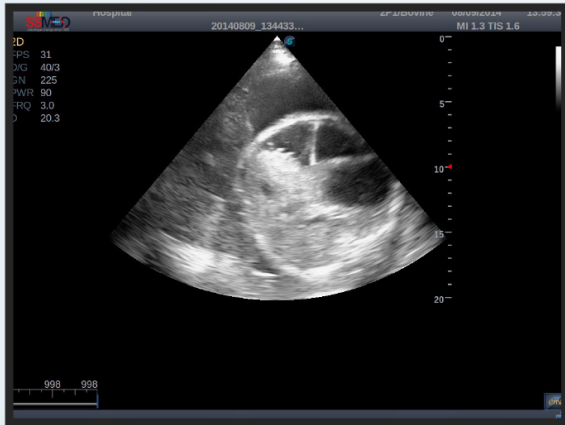
Recognition

- gestation sac,
- fetal parts,
- heart beat

Fetal heart with alternate hyerechoic ribs

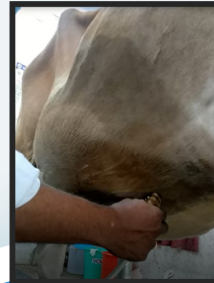
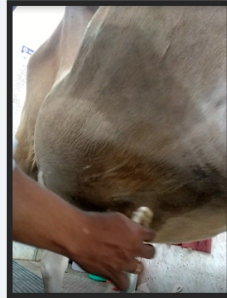


Pregnancy



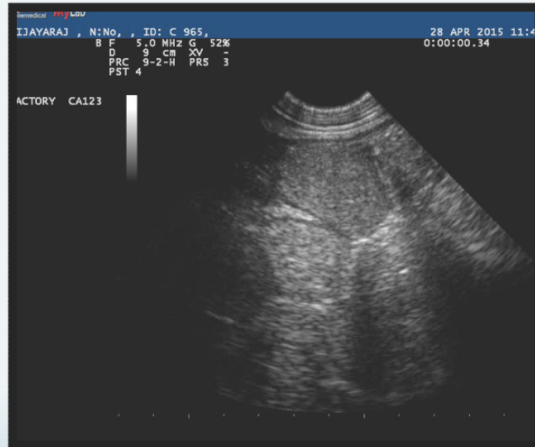
Small intestine

- Area from tuber coxae to the 8th i/c space
- Transverse processes of the vertebrae to the linea alba on the right side
- Diameter is 2 to 4 cm

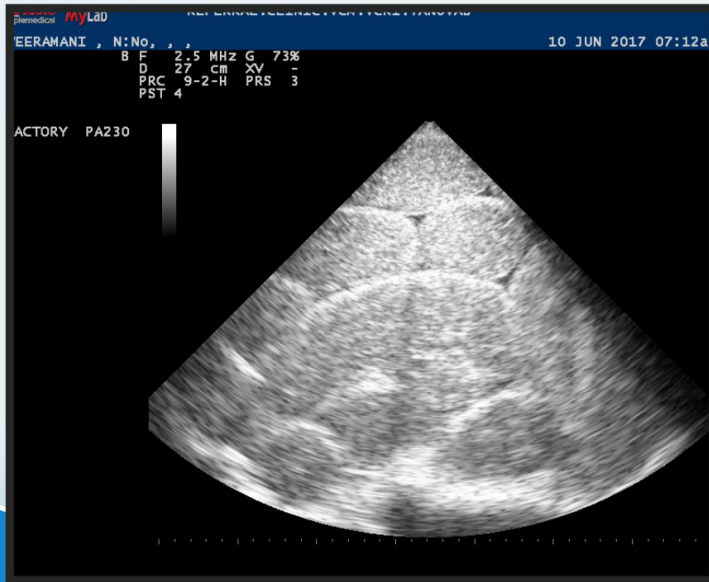


Normal small intestine

- Loops in cross-section and occasionally longitudinally



Loops of small intestine

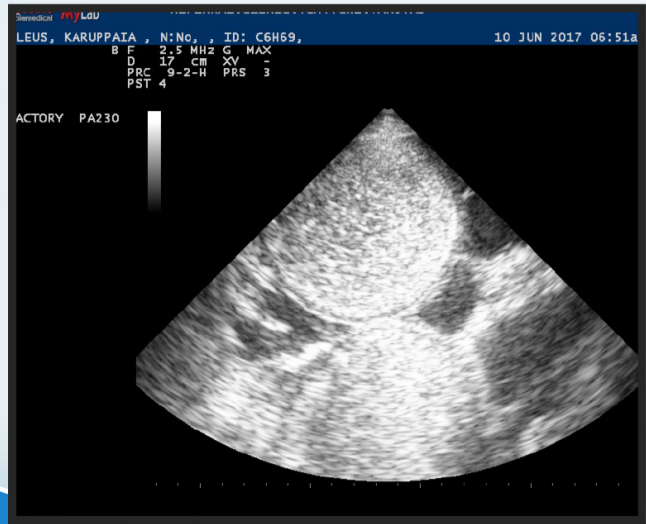


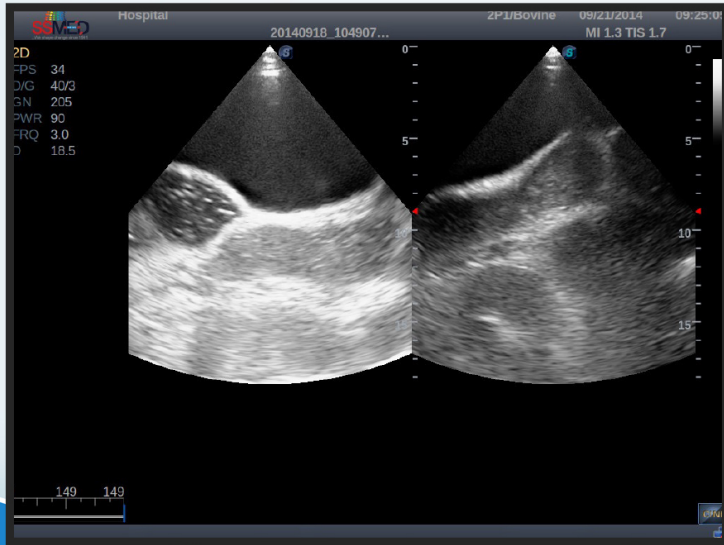
Dilated Caecum

- Gas
- Wall of the large intestine --thick echogenic line
- Echogenic, semi-circular lines

Ileus

- Diameter
- Motility
- Evidence of peritonitis





Ileus

- **FLUIDS and electrolytes**

- Calcium : 1 gram / 45 kg BW, IV

- Potassium : 0.5 mEq / kg BW, IV

- Phosphorous : 10 milligram/ kg BW, IV

(4-(Dimethylamino)-2-methylphenyl
phosphinic acid

diluted in normal saline

Ileus

- Neostigmine (0.02 /kg body weight)

(Lester et al., 1998b)

Ileus

- Metoclopramide (0.1 mg/kg body weight)

(Roussel et al., 1994)

Ileus

- Erythromycin 8.8 mg/kg IV for three days

(Constable et al., 2012; Sanger et al., 2013)



*Thank
you*