



Unit : Intestinal stasis in cattle

Lesson : 3

Radiography and Ultrasonography

Dr. G. Vijayakumar, M.V.Sc., Ph.D., PGDECM

Professor

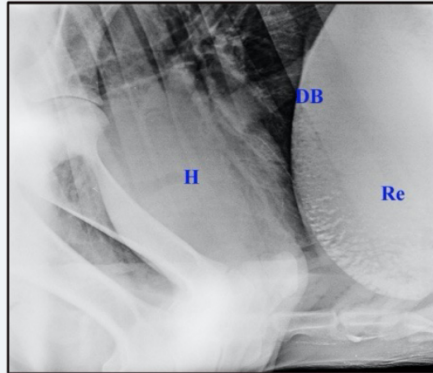
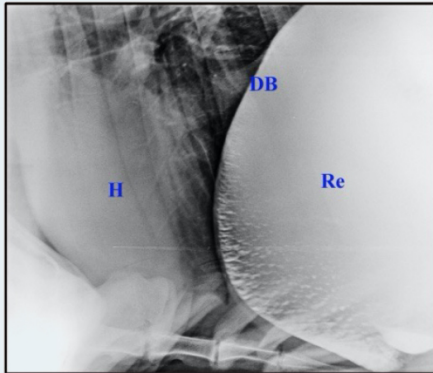
Veterinary University Peripheral Hospital

Madhavaram Milk Colony

Chennai-600 051

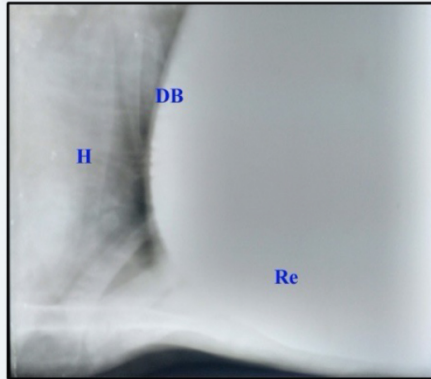
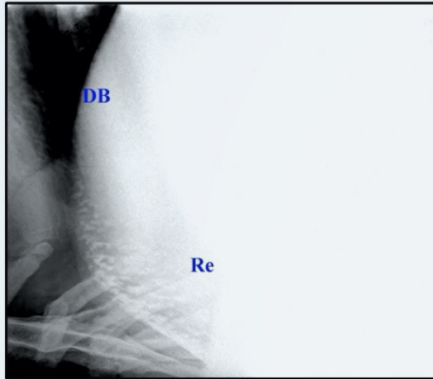
Tamil Nadu Veterinary and Animal Sciences University

Radiography




H : Heart
DH : Diaphragm
Re : Reticulum

Radiography – Contrast

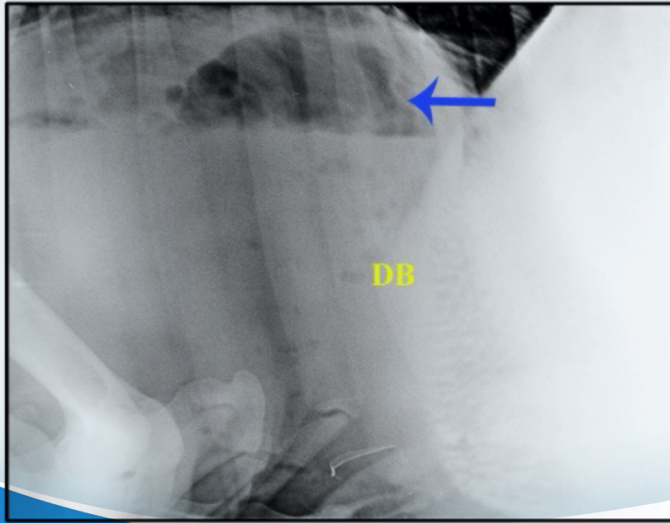


H : Heart
DB : Diaphragm
Re : Reticulum

Radiography- FB



Radiography- DH



Ultrasonography



Pericarditis

Echocardiograms

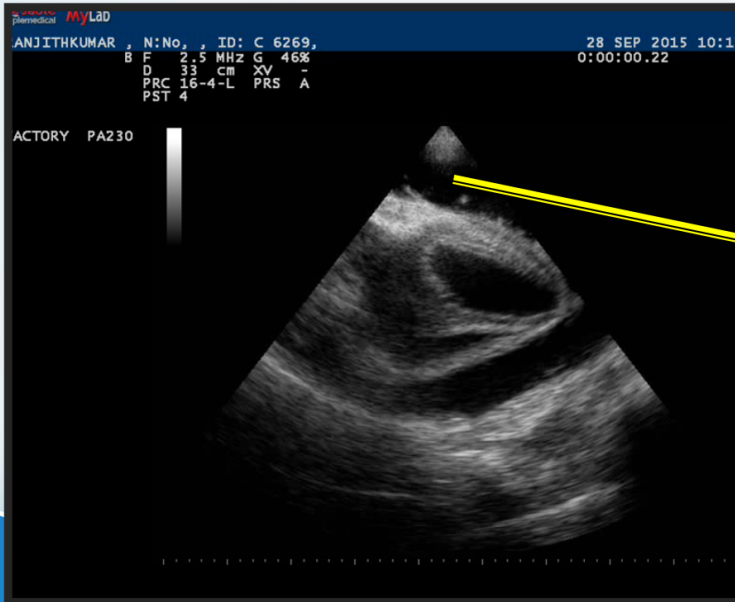
- Standing animals
- 3rd to 5th inter costal space
- Thoracic limb - cranially or abducted
- Short axis view or
- Long axis view

Pericarditis

Ultrasonographic Features

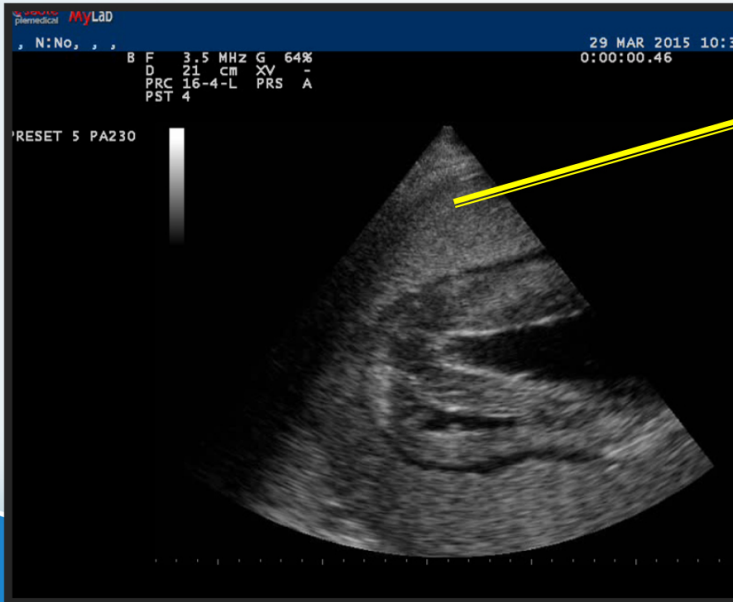
- Pericardial effusion -- hypoechoic to echogenic
- Echoic fibrin clots can also be seen
- Thick echoic membrane surrounding the heart

Pericarditis



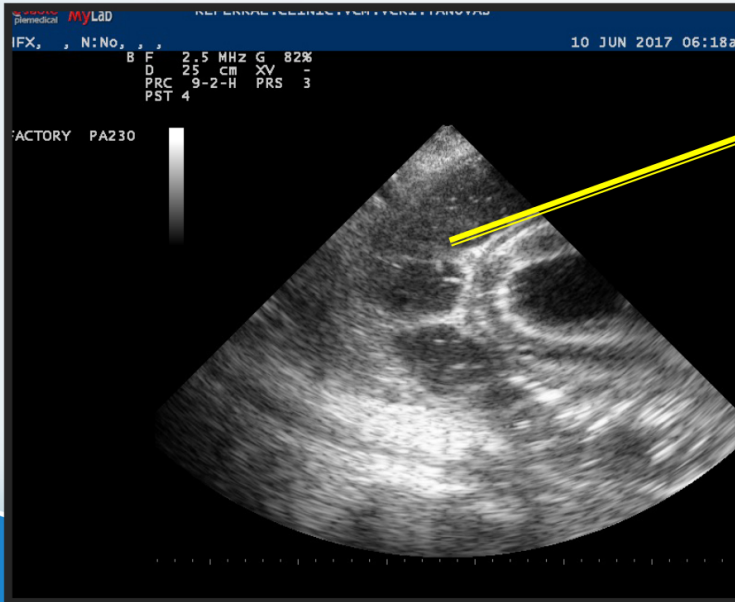
Anechoic

Pericarditis



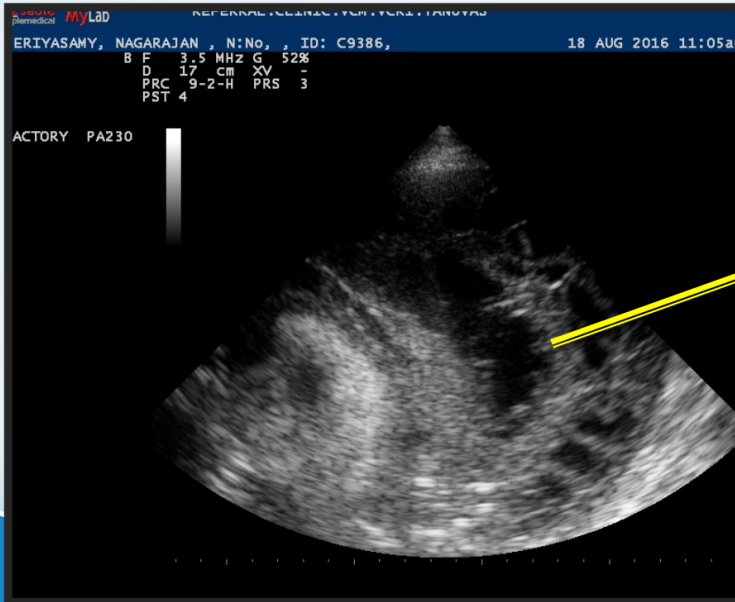
Echogenic

Pericarditis



Fibrin

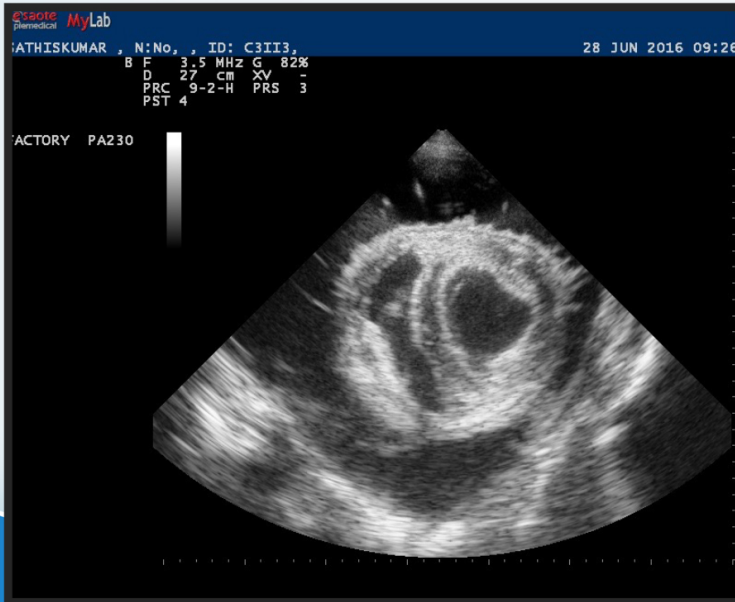
Pericarditis

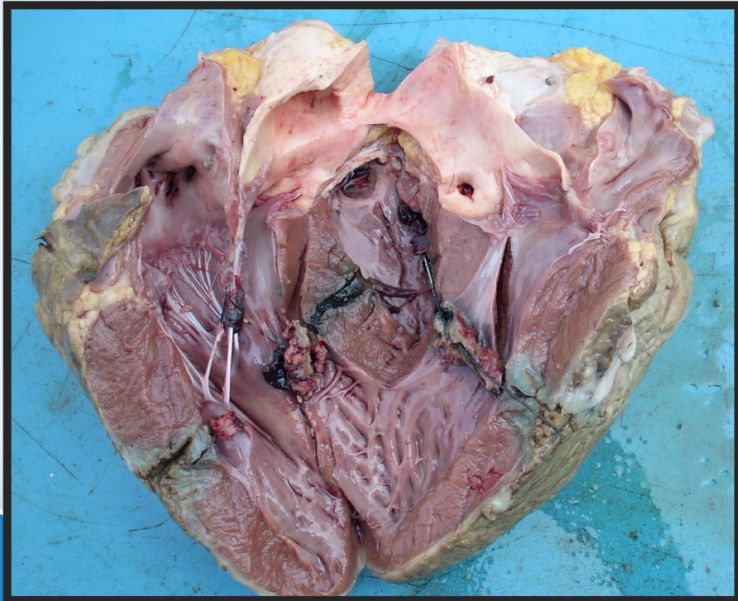


Extensive fibrin

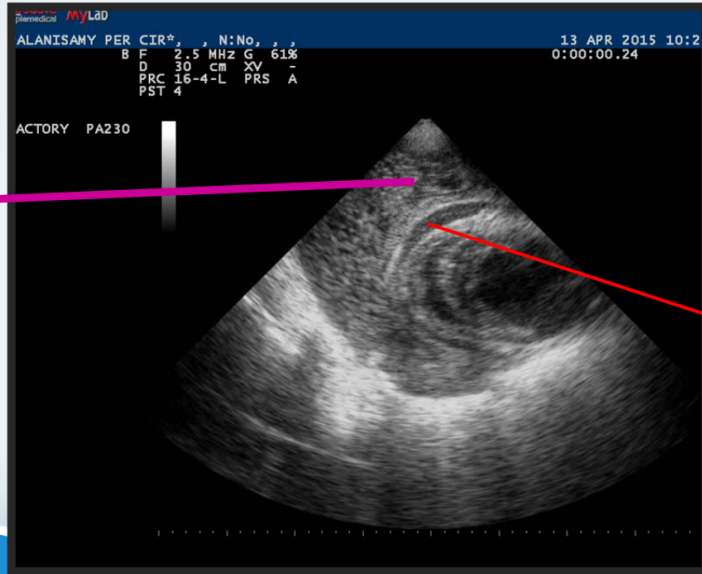


Pericarditis





Pleural Effusion



Pleural effusion

Pleural effusion



*Thank
you*