

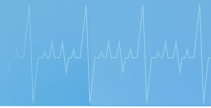

Unit : Hypomagnesaemic Tetany in Cattle

Lesson : 2


Pathogenesis, Clinical findings

Dr.S.Kavitha, Ph.D.,

Professor and Head
Department of Veterinary Clinical Medicine,
Madras Veterinary College,
Chennai - 600 007. Tamilnadu



Pathogenesis



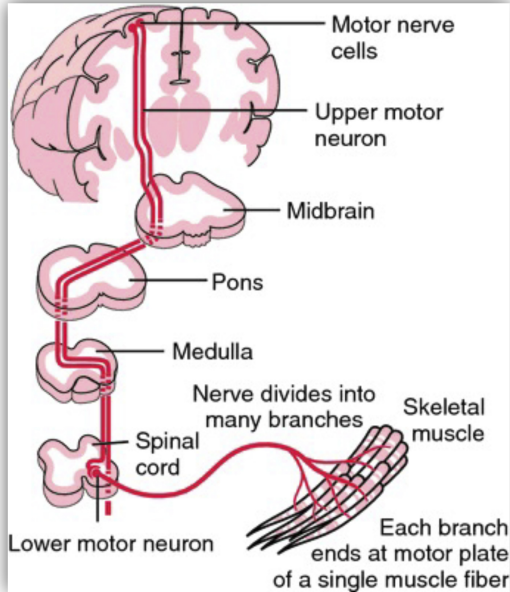
Endogenous loss in faeces (2.8g/day)

Urine loss (0-4g/day)

Milk (0.15g/L)
(3 – 7.5g/day)

Dietary absorption via intestine (20%)

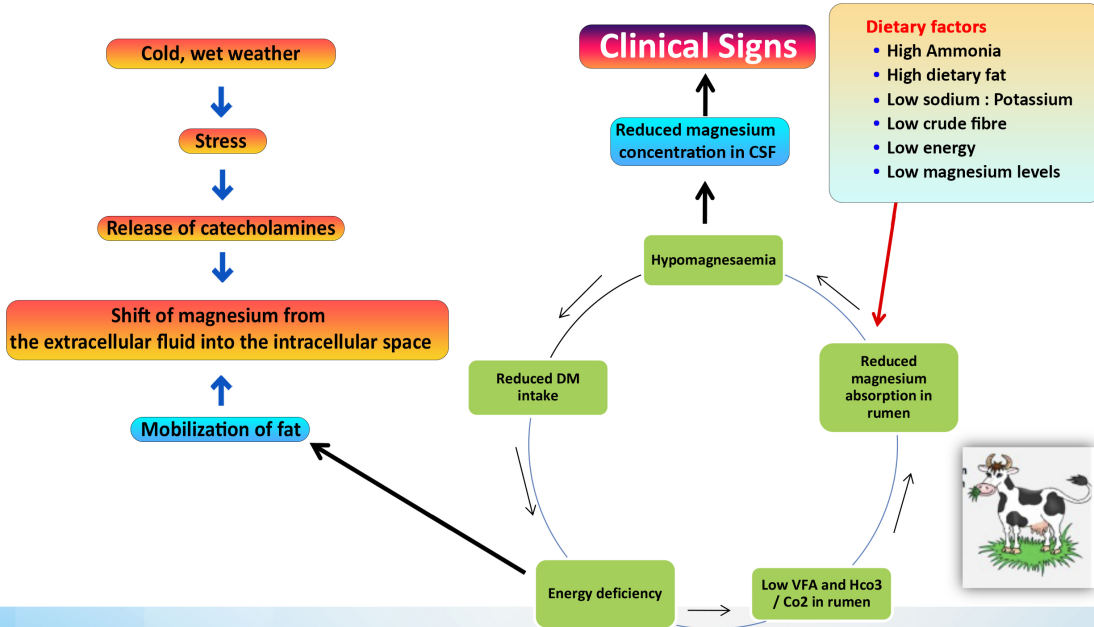
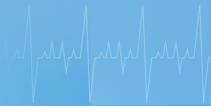Pathogenesis

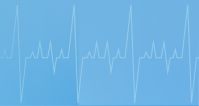

- **Clinical signs - <1 mg/dL (Normal - 1.7 to 3.0 mg/dL).**
- **Mg low in the CSF than serum**
- **CNS signs**

- **Impulse transmission**
- **Release of acetylcholine**
- **Sensitivity of motor end plate**
- **Activation choline esterase system**

Muscular irritation





Acute Hypomagnesaemic

- **The animal may be grazing at the time and suddenly cease to graze, adopt a posture of unusual alertness and appear uncomfortable.**
- **Twitching of the muscles and ears is also evident. There is severe hyperesthesia and slight disturbances precipitate attacks of continuous bellowing, frenzied galloping, and occasionally aggression.**

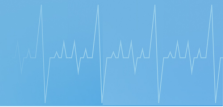

Clinical Findings

Opisthotonos

- Nystagmus
- Champing of the jaws
- Frothing at the mouth
- Pricking of the ears
- Retraction of the eyelids.
- Sudden death





Pricking of the ears





Other clinical signs

- ▶ **The temperature rises to 40-40.5°C (104-105°F) after severe muscle exertion.**
- ▶ **The pulse and respiratory rates are also high.**
- ▶ **The absolute intensity of the heart sounds is increased so that they can be heard some distance away from the cow.**
- ▶ **Death usually occurs within 5-1 h and the mortality rate is high because many die before treatment can be provided**



Sub acute Lactation Tetany

- ▶ **Onset is more gradual (3 to 4 days)**
- ▶ **wildness of the facial expression and exaggerated limb movements.**
- ▶ **Spasmodic urination and frequent defecation are characteristic**
- ▶ **The appetite and milk yield are diminished and ruminal movements decrease.**



- ▶ **Muscle tremor and mild tetany of the hind legs and tail with an unsteady, straddling gait may be accompanied by retraction of the head and trismus.**
- ▶ **Sudden movement or noise, the application of restraint, or the insertion of a needle may precipitate a violent convulsion**



Chronic Lactation Tetany

- ▶ **Many animals in affected herds have low serum magnesium levels but do not show clinical signs**
- ▶ **Dullness, unthriftiness, and indifferent appetite and may subsequently develop one of the more obvious syndromes**
- ▶ **Depressed milk production**



Thank you