



# Recent techniques for diagnosis of chicken coccidiosis

**Dr. T. Anna** , M.V.Sc., Ph.D.,  
Professor and Head,  
Dept. of Veterinary Parasitology,  
Veterinary College and Research Institute,  
Tirunelveli – 627 358, Tamil Nadu.



# Recent techniques for diagnosis of chicken coccidiosis



# Recent techniques for diagnosis of chicken coccidiosis

**Estimation of litter oocyst density (OPG)**

***In-vitro* Sporulation of coccidia**

**Lesion Scoring Technique (GLS/MLS)**

**Immunodiagnosis of chicken coccidiosis**

**Biochemical and Molecular detection of coccidiosis**



## Laboratory Procedures

- **Autopsy of suspected bird**
- **Carcass observation**
- **Mucosal scraping – Microscopic examination**
- **Giemsa's Staining**
- **Lesions Score**



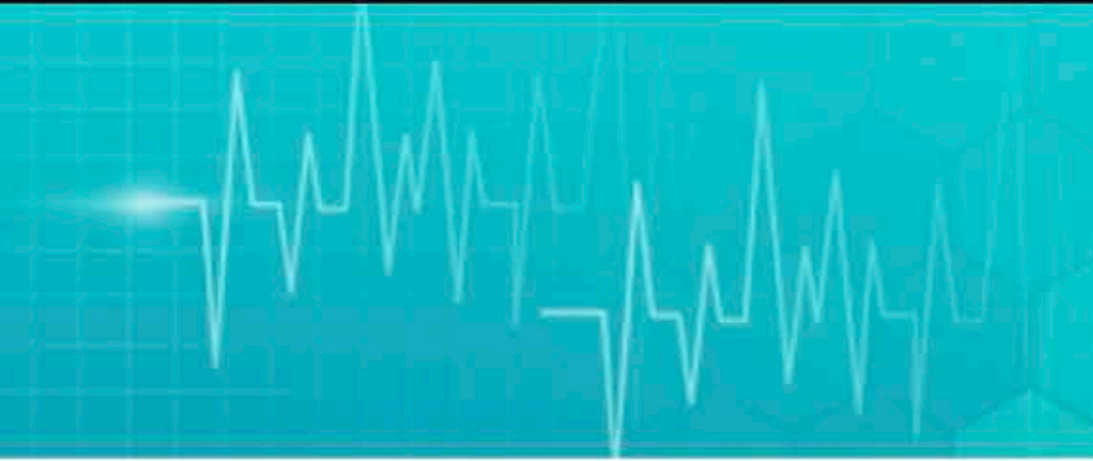## **SPECIATION / PARASITOLOGICAL DIAGNOSIS**

- **Coprological exam of fresh droppings / rectal contents – Concentration tech.**
- **Coproculture – sporulation time, oocyst morphology, morphometry, shape index**
- **Quantitative studies to estimate OPG**
- **Histopathology of sections (H&E stain)**



## Examination of litter samples

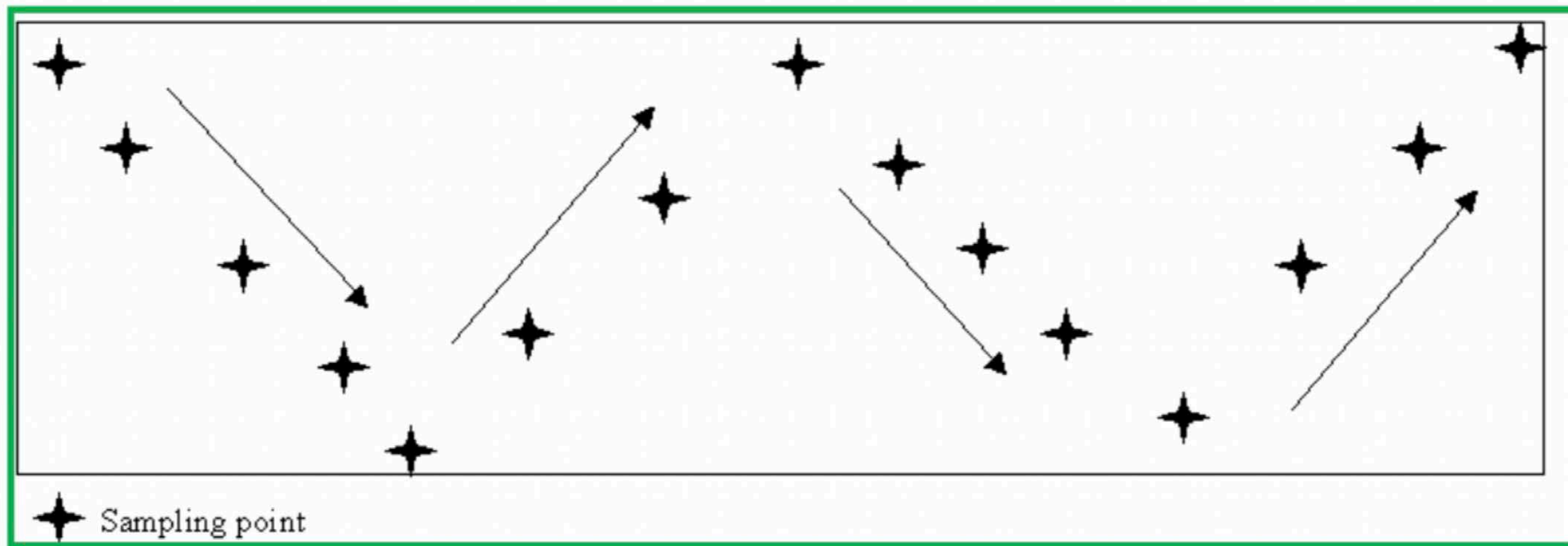
- ▶ **Periodical, systematic, random collection of samples**
- ▶ **Processed by standard method**  
**Estimating Oocyst density (OPG) using**
- ▶ **McMaster's Technique (Counting chamber)**



# Estimation of litter oocyst density

## Litter Sampling Methods

Approximate position of sampling points  
(for shed with 10,000 broilers)

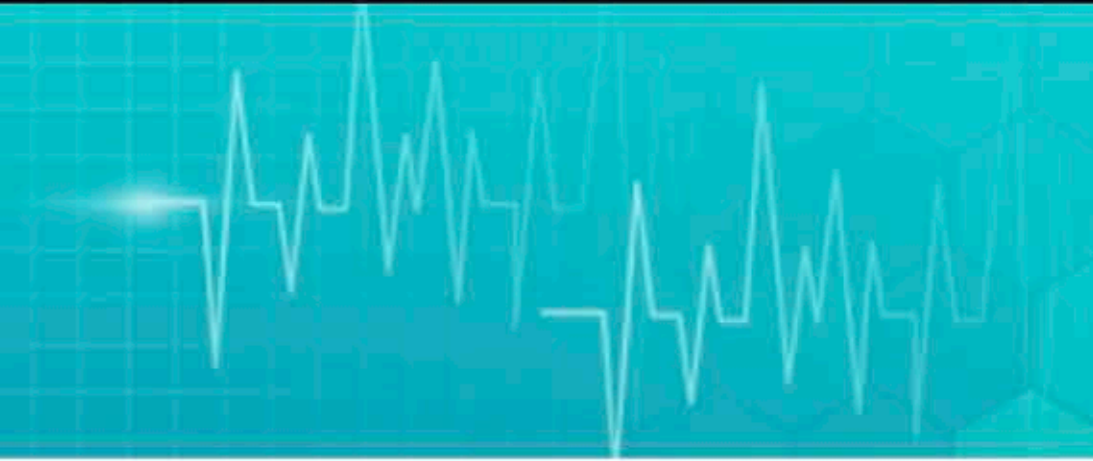




# LITTER OOCYST COUNTING PROCEDURE

- ▶ **Mix well the contents of the litter sample bag by shaking it thoroughly**
- ▶ **Weigh 2 samples of 10 grams of litter**
- ▶ **Run the 2 samples as duplicates and record both counts separately**
- ▶ **McMaster's counting chamber**
- ▶ **Count the floating oocysts using a microscope**
- ▶ **Calculate the number of oocysts per gram (OPG) of litter by multiplying the counted oocysts by 100**






# 2 CELL McMASTER COUNTING SLIDE



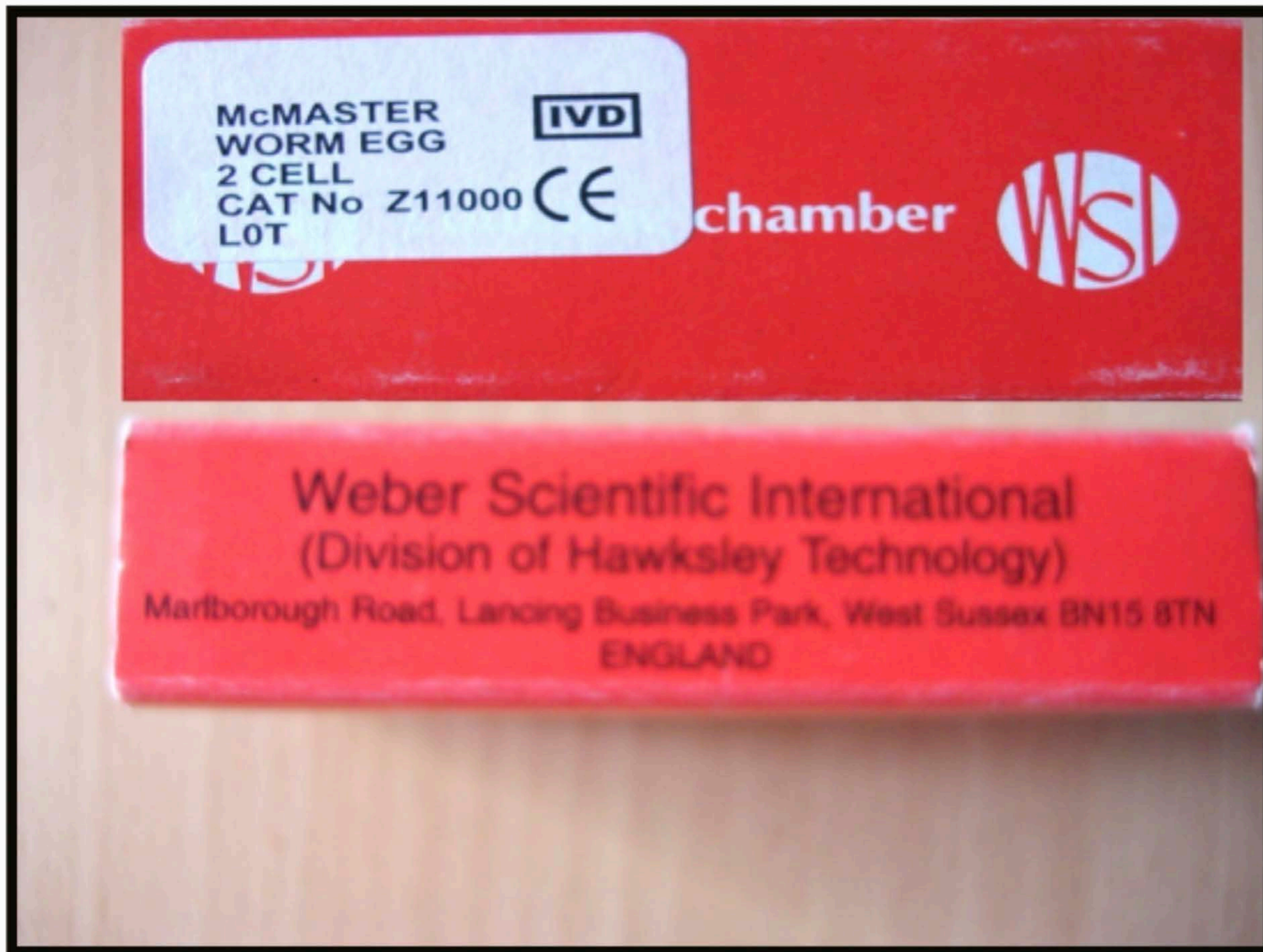


# 2 CELL McMASTER COUNTING SLIDE





# 2 CELL McMASTER COUNTING SLIDE



## Calculation of OPG

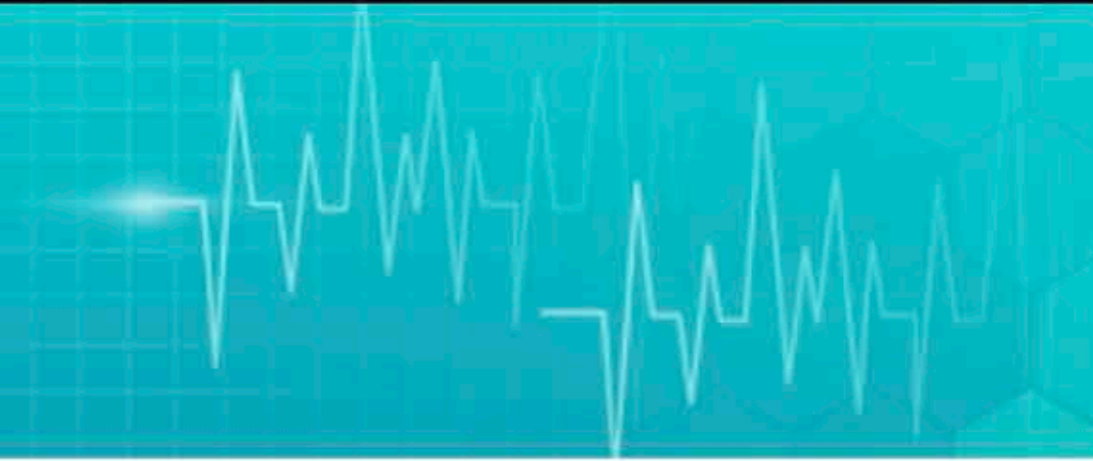$$\text{OPG} = \frac{X_1 + X_2}{2} \times 100$$

Where  $X_1$  = No. of oocysts in chamber 1

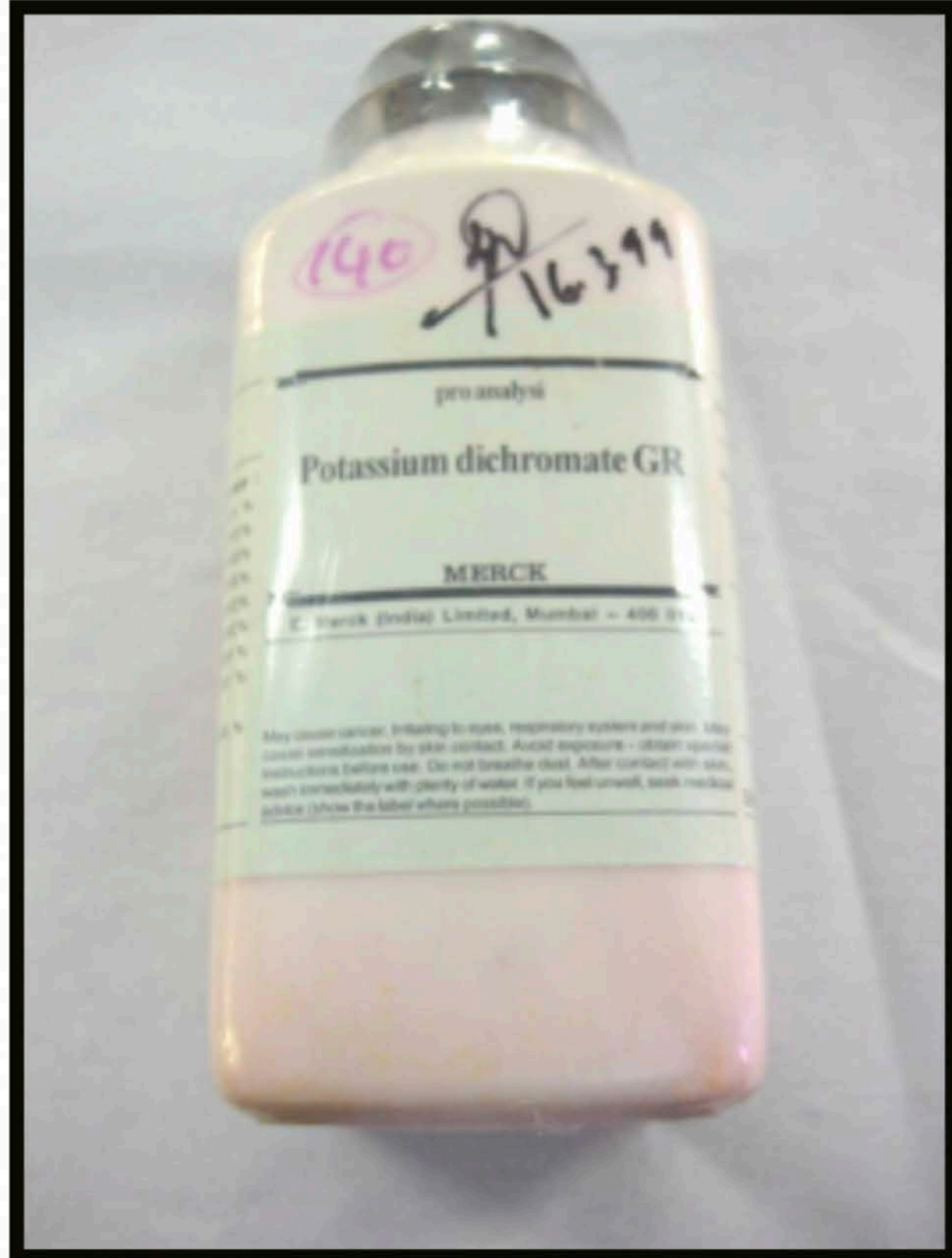$X_2$  = No. of oocysts in chamber 2


100 = Multiplication factor

# Technique for *In-vitro* sporulation of coccidial oocysts




# Step wise Procedure for *In-vitro* sporulation of coccidial oocysts






# Step wise Procedure for *In-vitro* sporulation of coccidial oocysts





# Step wise Procedure for *In-vitro* sporulation of coccidial oocysts







# Step wise Procedure for *In-vitro* sporulation of coccidial oocysts






# Step wise Procedure for *In-vitro* sporulation of coccidial oocysts



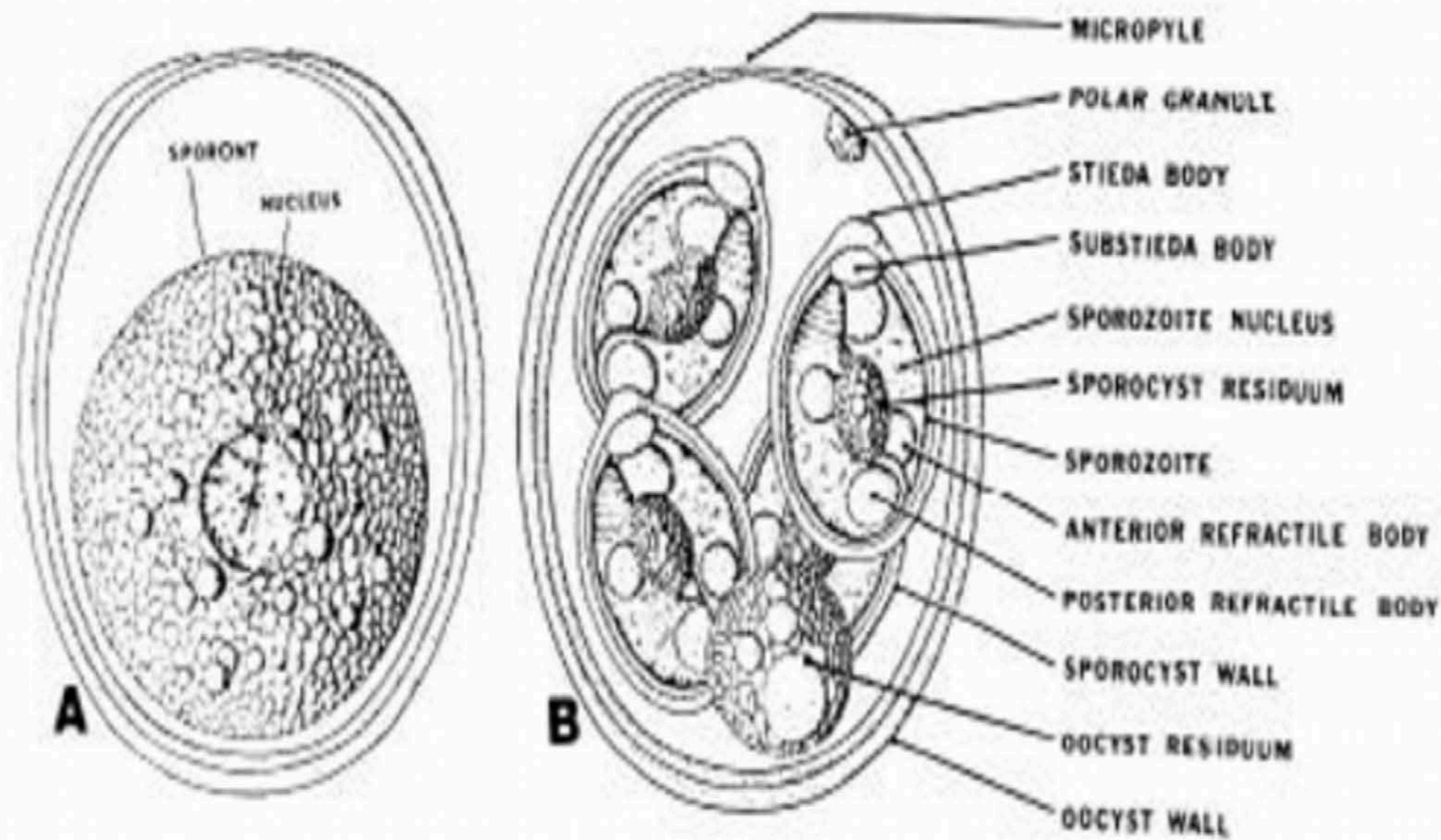


# Step wise Procedure for *In-vitro* sporulation of coccidial oocysts



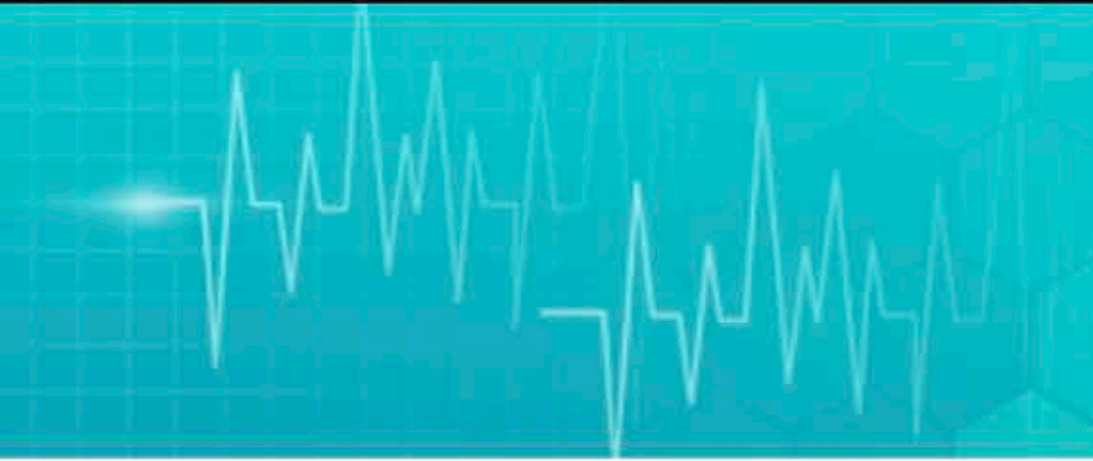

# Unsporulated and Sporulated oocysts of *Eimeria* spp

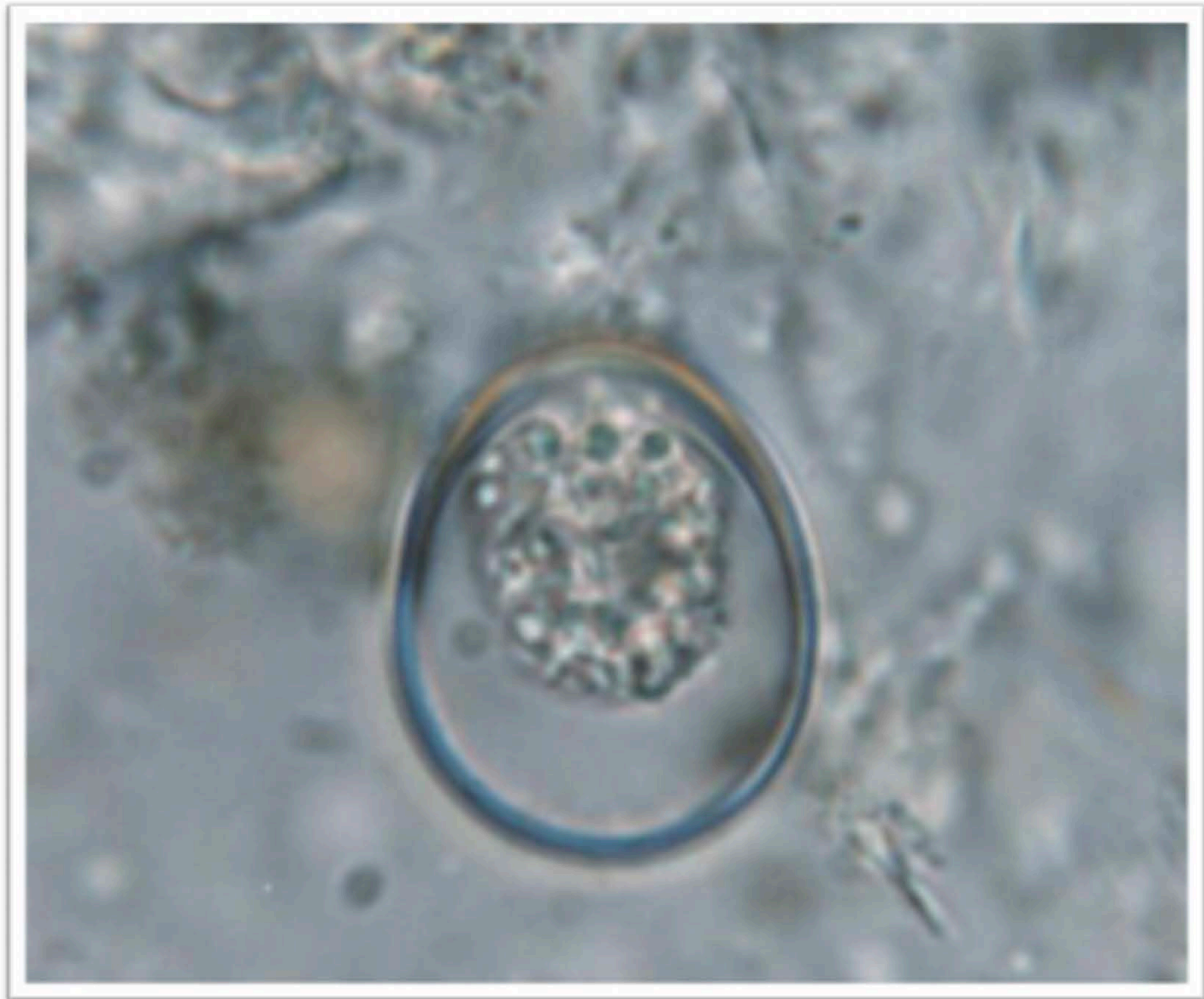


unsporulated

sporulated

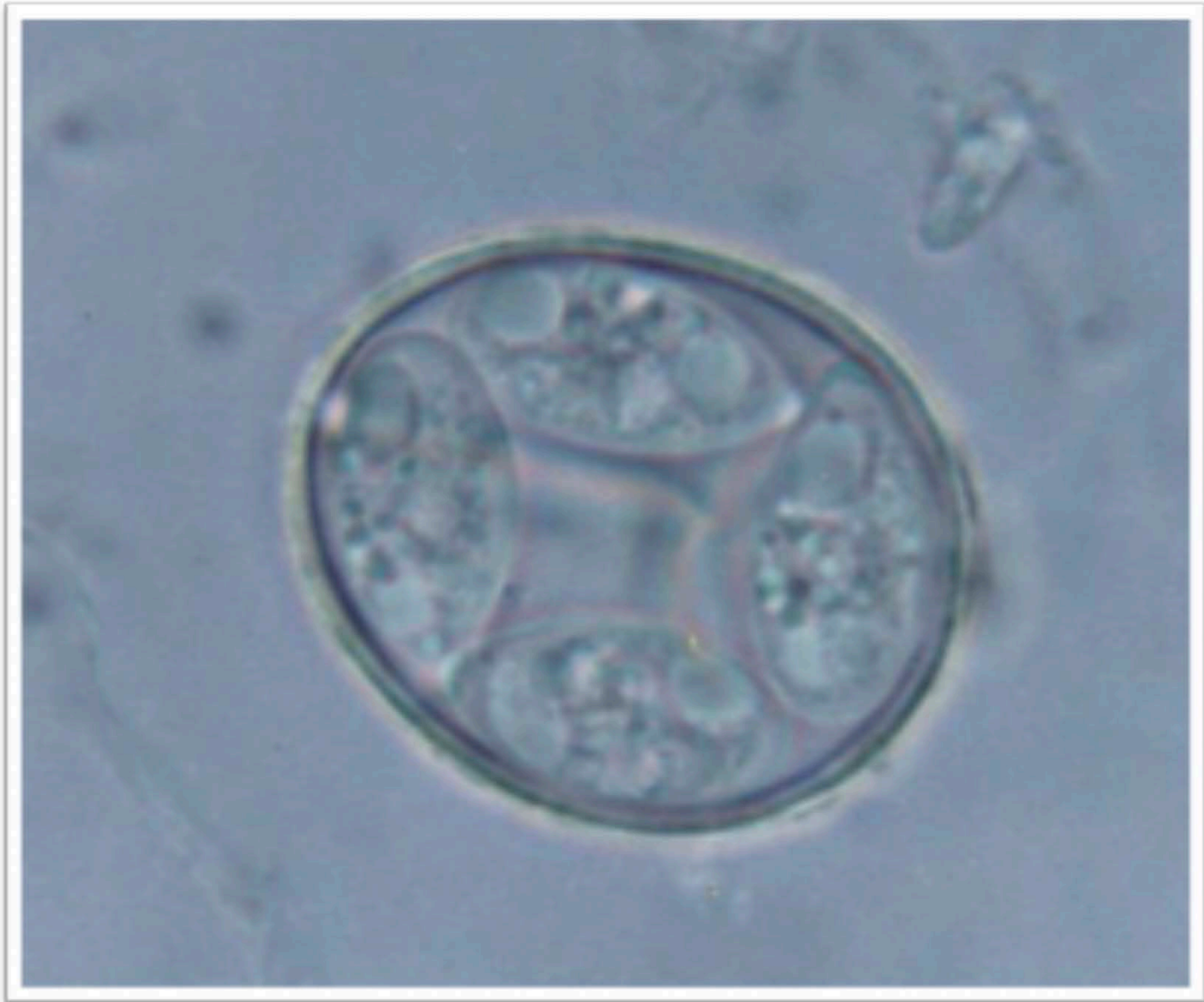


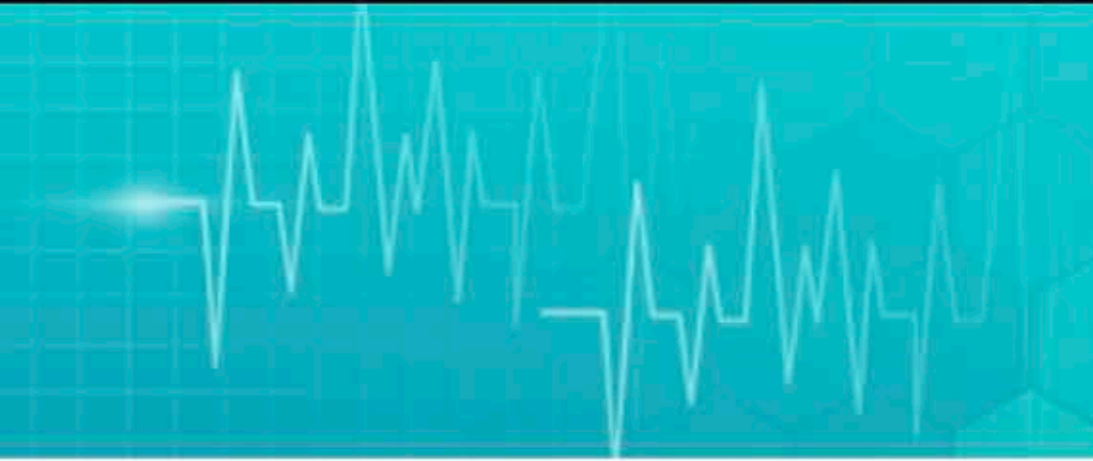# *Eimeria* – Unsporulated Oocyst





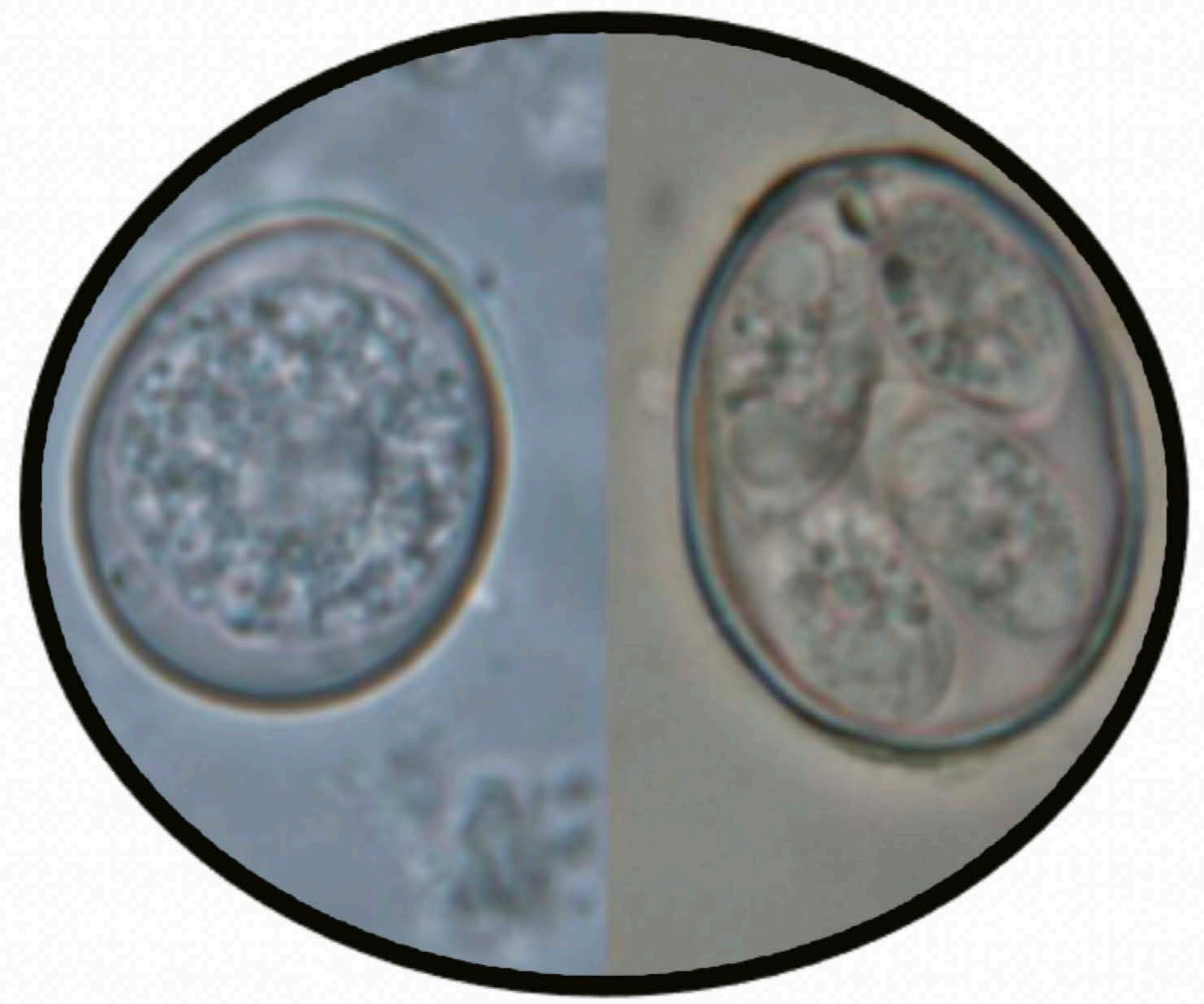# *Eimeria tenella* – Sporulated oocyst

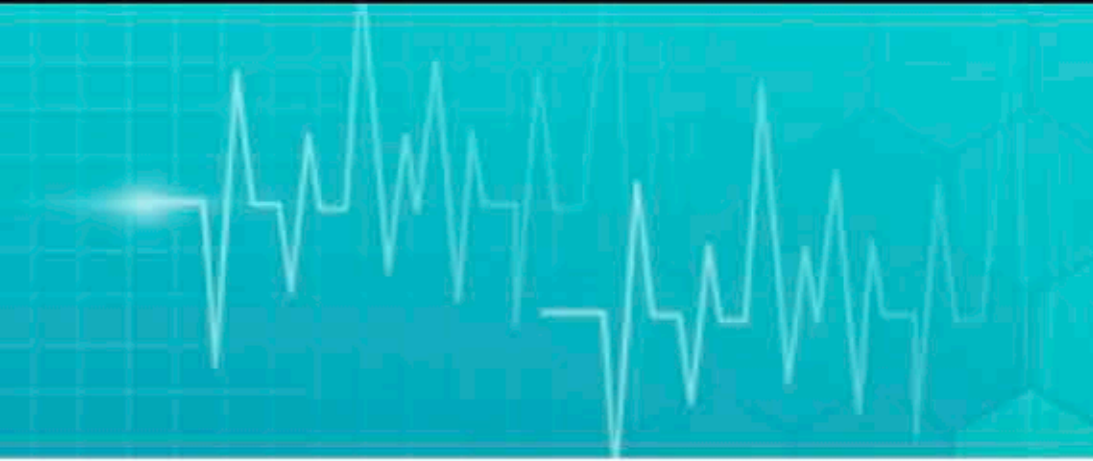



# *Eimeria necatrix* –

## *Unsporulated and Spoulated Oocyst*



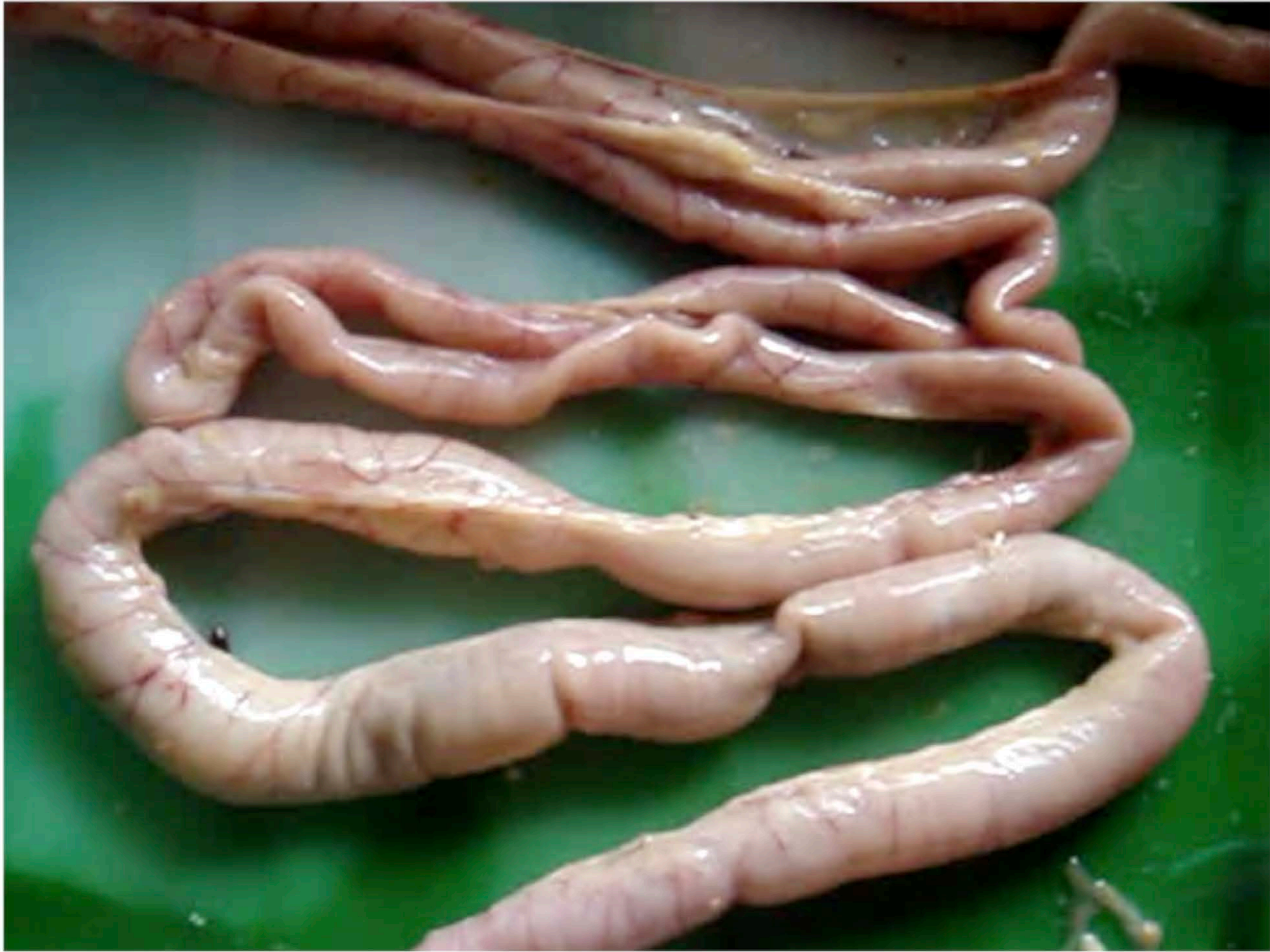

# LESION SCORING TECHNIQUE

- Johnson and Reid Method

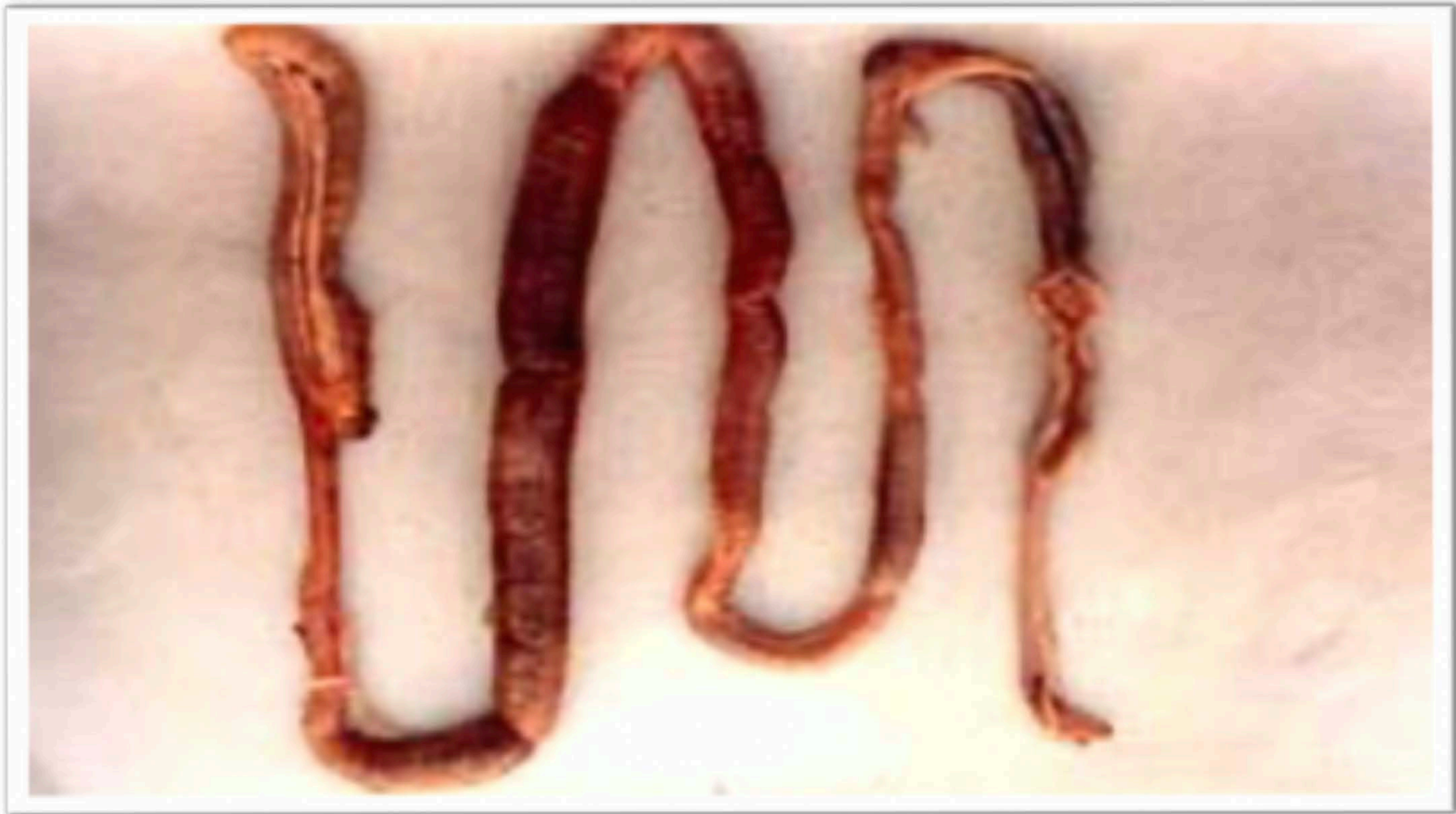




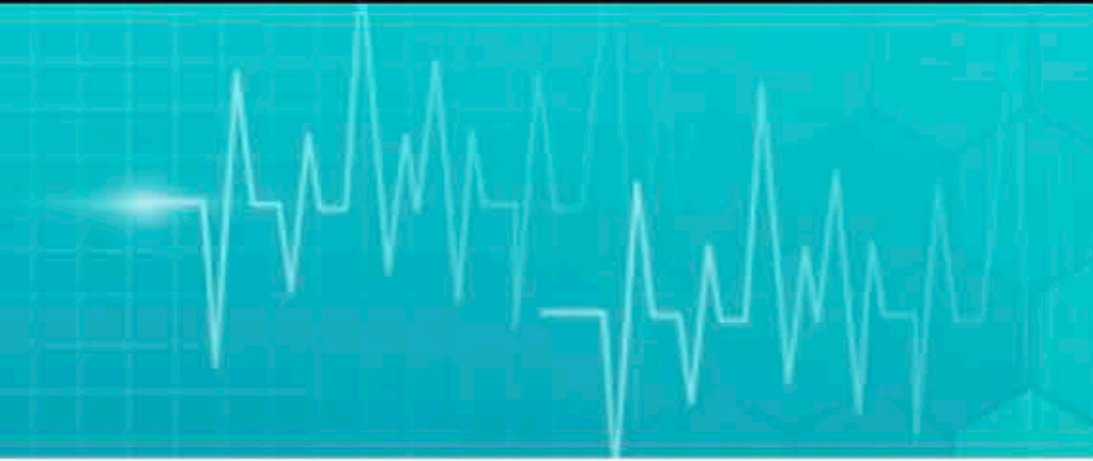


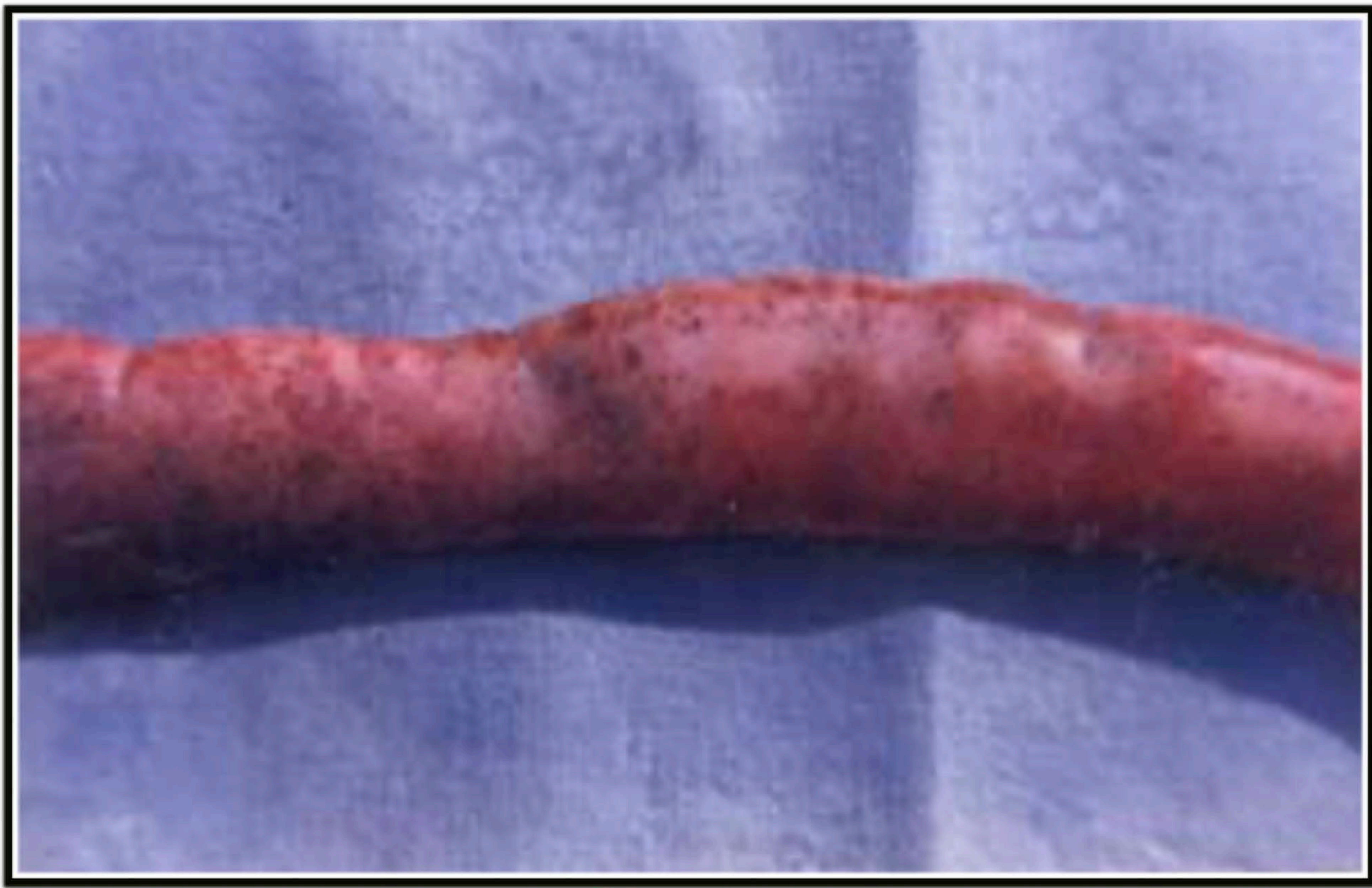# GROSS LESION SCORING TECHNIQUE



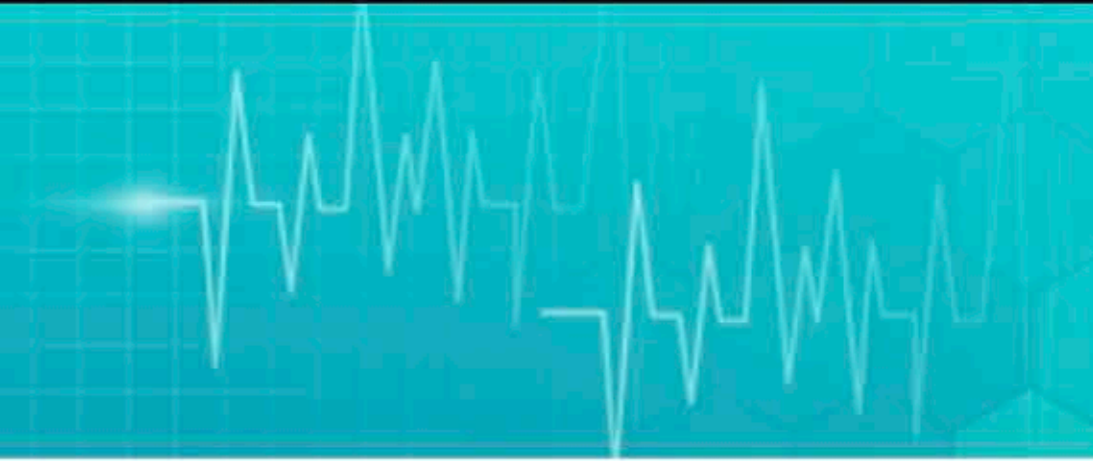**Gross Appearance**



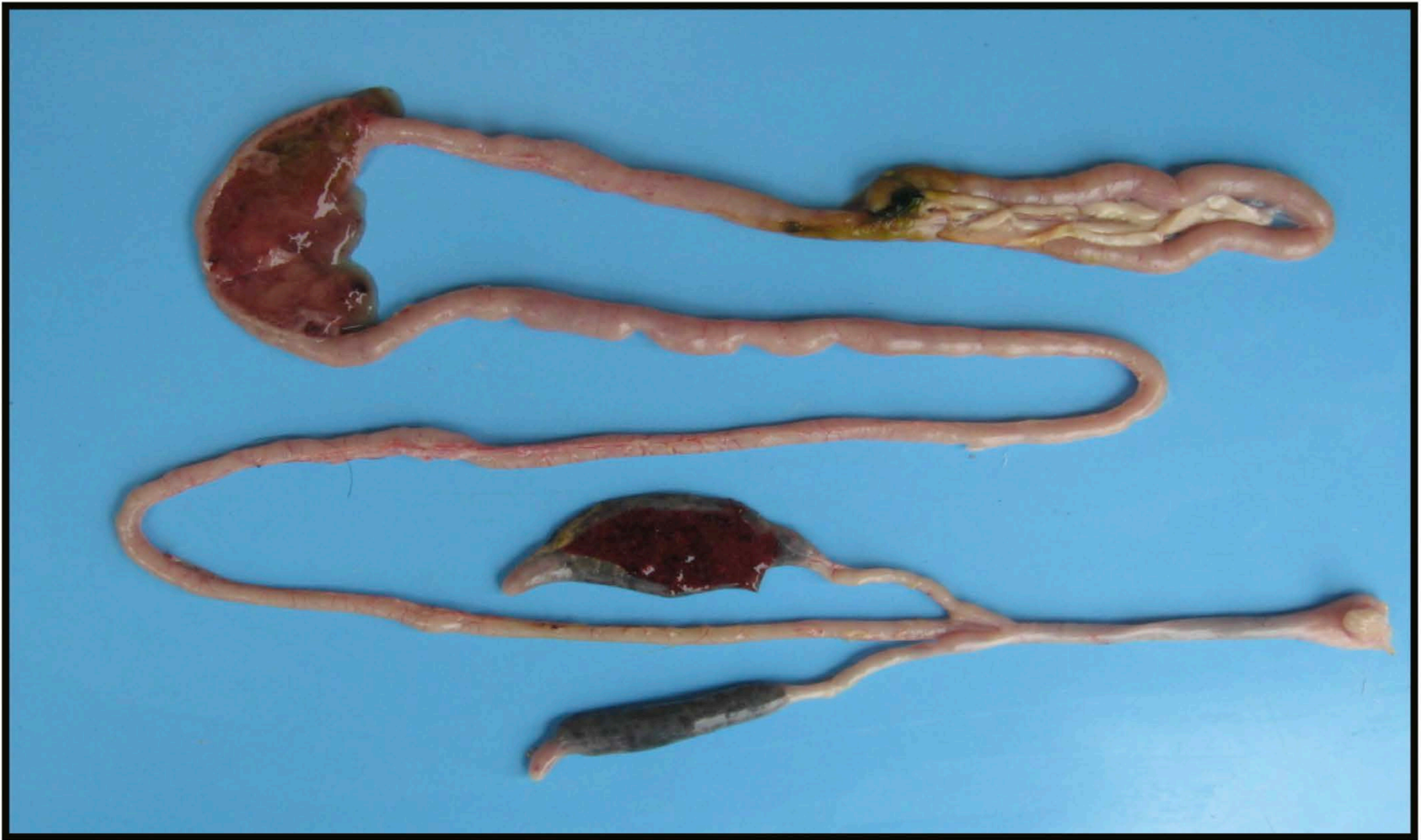# GROSS LESION SCORING TECHNIQUE



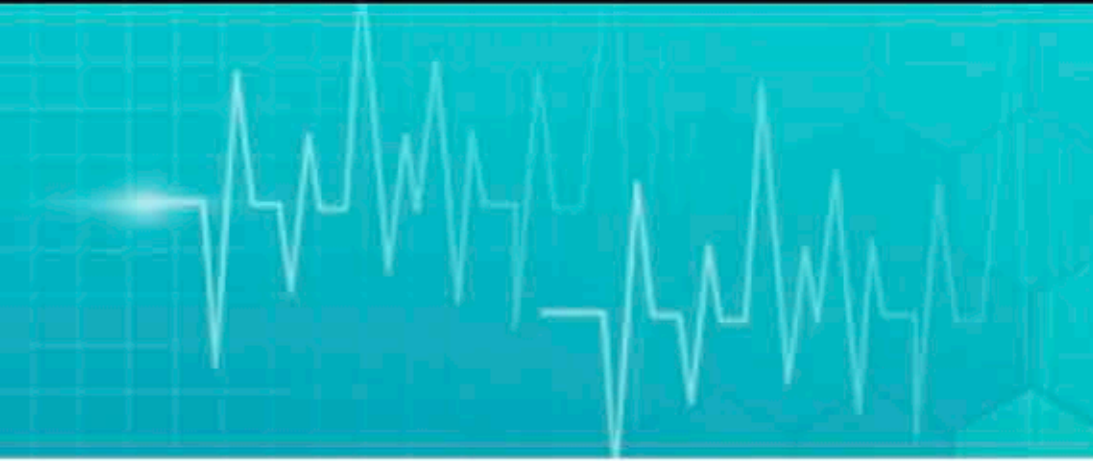**No. of lesions**



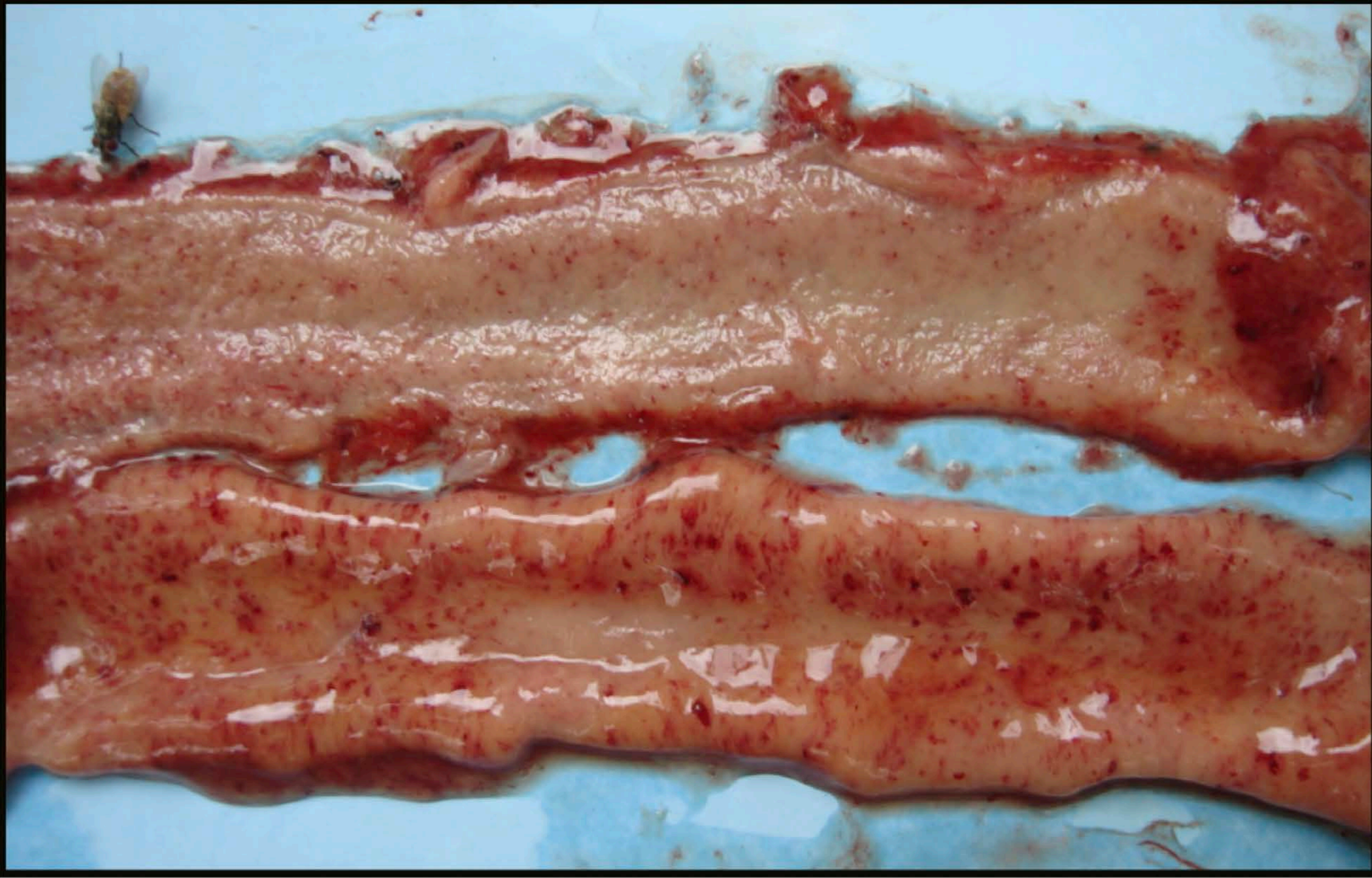
# GROSS LESION SCORING TECHNIQUE



**Intestinal contents**



# GROSS LESION SCORING TECHNIQUE



**Intestinal wall thickness and lesions**

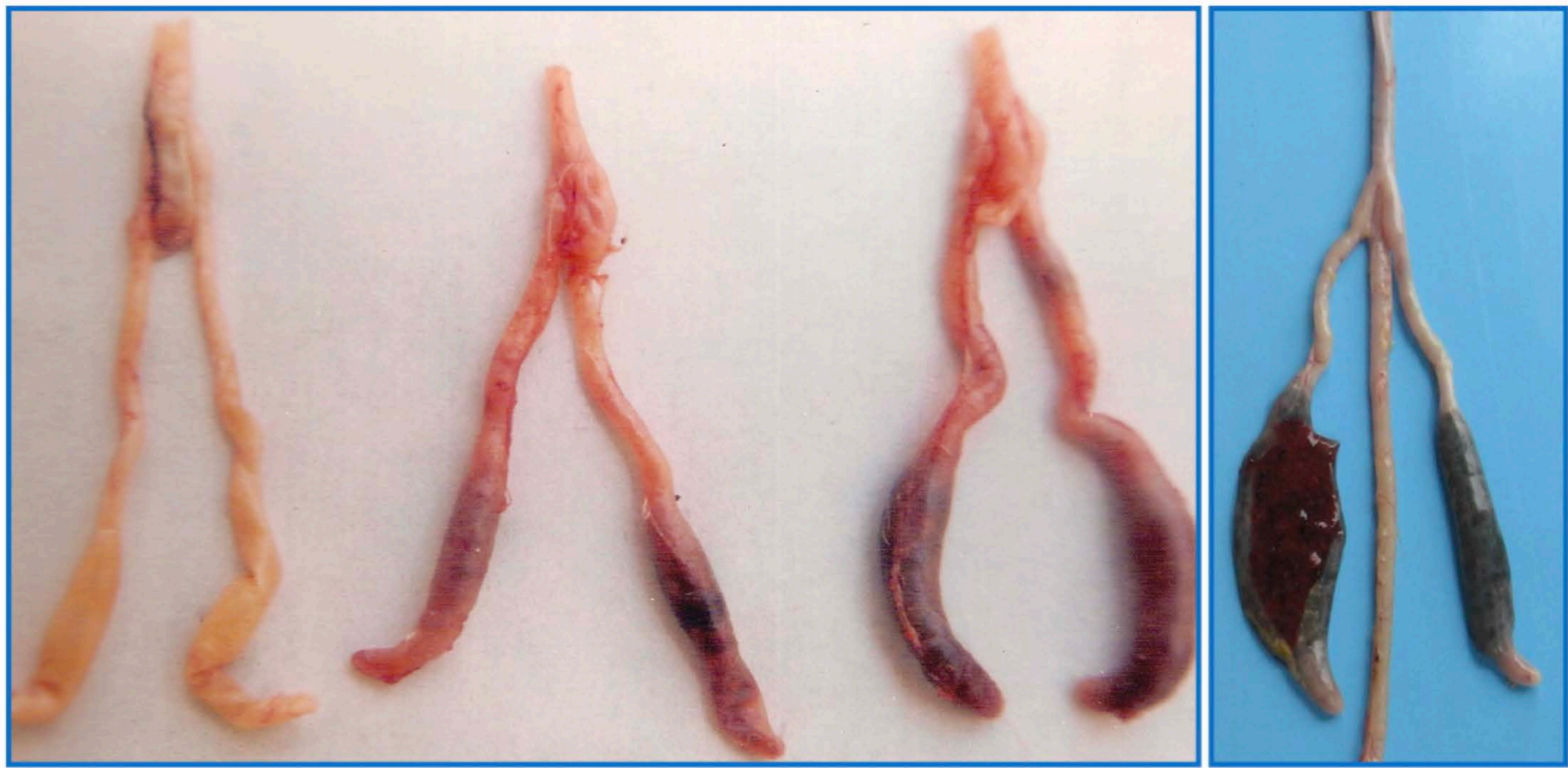
# LESION SCORE CARD

## *E.tenella*

Lesions	Scoring 1	Scoring 2	Scoring 3	Scoring 4 (dead birds)
<b>Gross Appearance</b>	scattered petechiae, white patches on serosa	numerous petechiae on serosa, violent red.	extensive red petechiae, and white plaques on serosa	dark colour, extensive haemorrhages
<b>Number of lesions</b>	scattered	numerous	numerous	coalescent
<b>Condition of Intestinal wall</b>	normal	swelling limited to central part	rough, thickened and swollen up to lower part	swelling over whole intestine
<b>Intestinal contents</b>	normal	normal	extensive haemorrhage, red or brown mucus	very dark red or brown mucus

# GROSS LESION SCORING TECHNIQUE

## CAECAL COCCIDIOSIS - *Eimeria tenella*



Lesion Score 1

Lesion Score 2

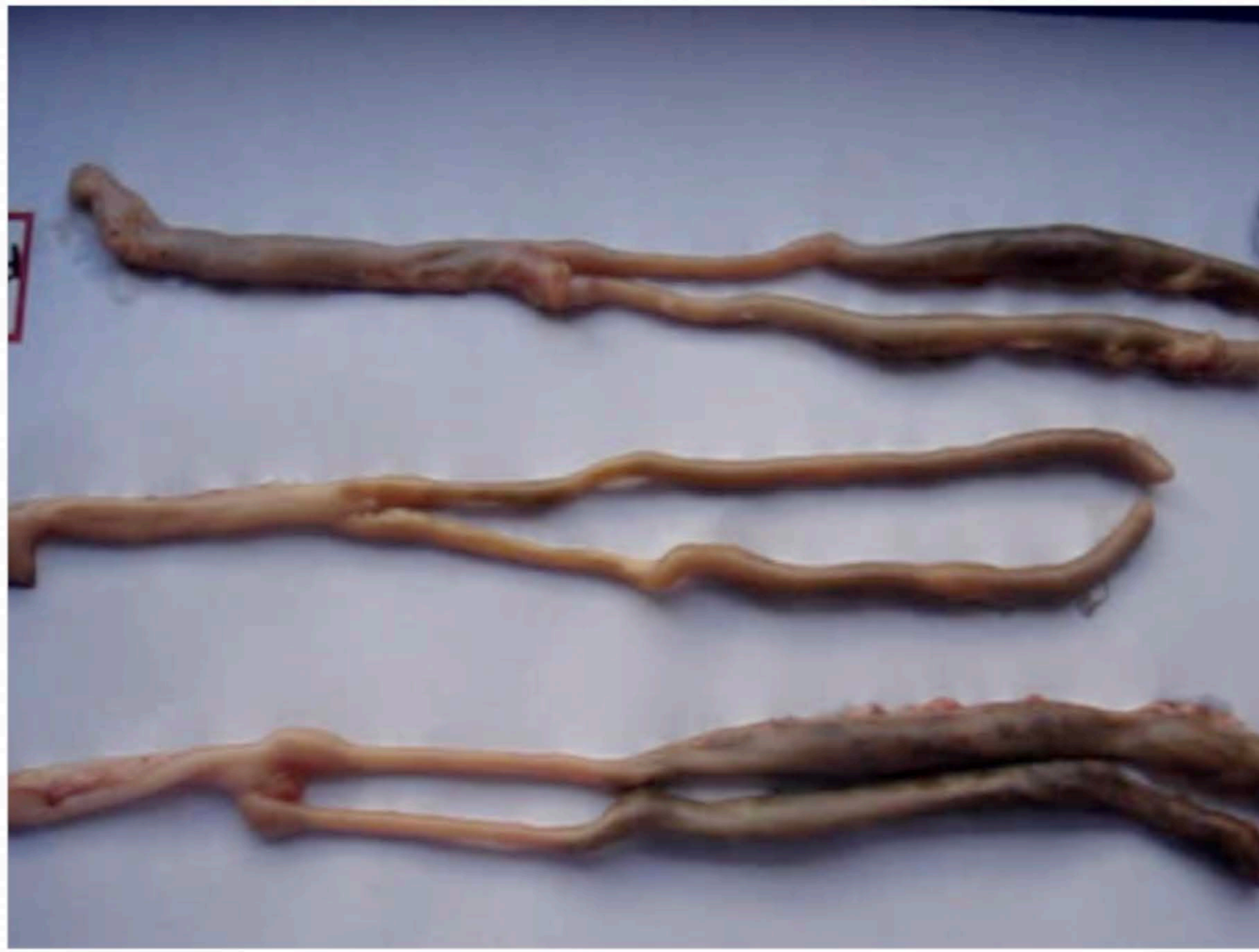Lesion Score 3

Lesion Score 4





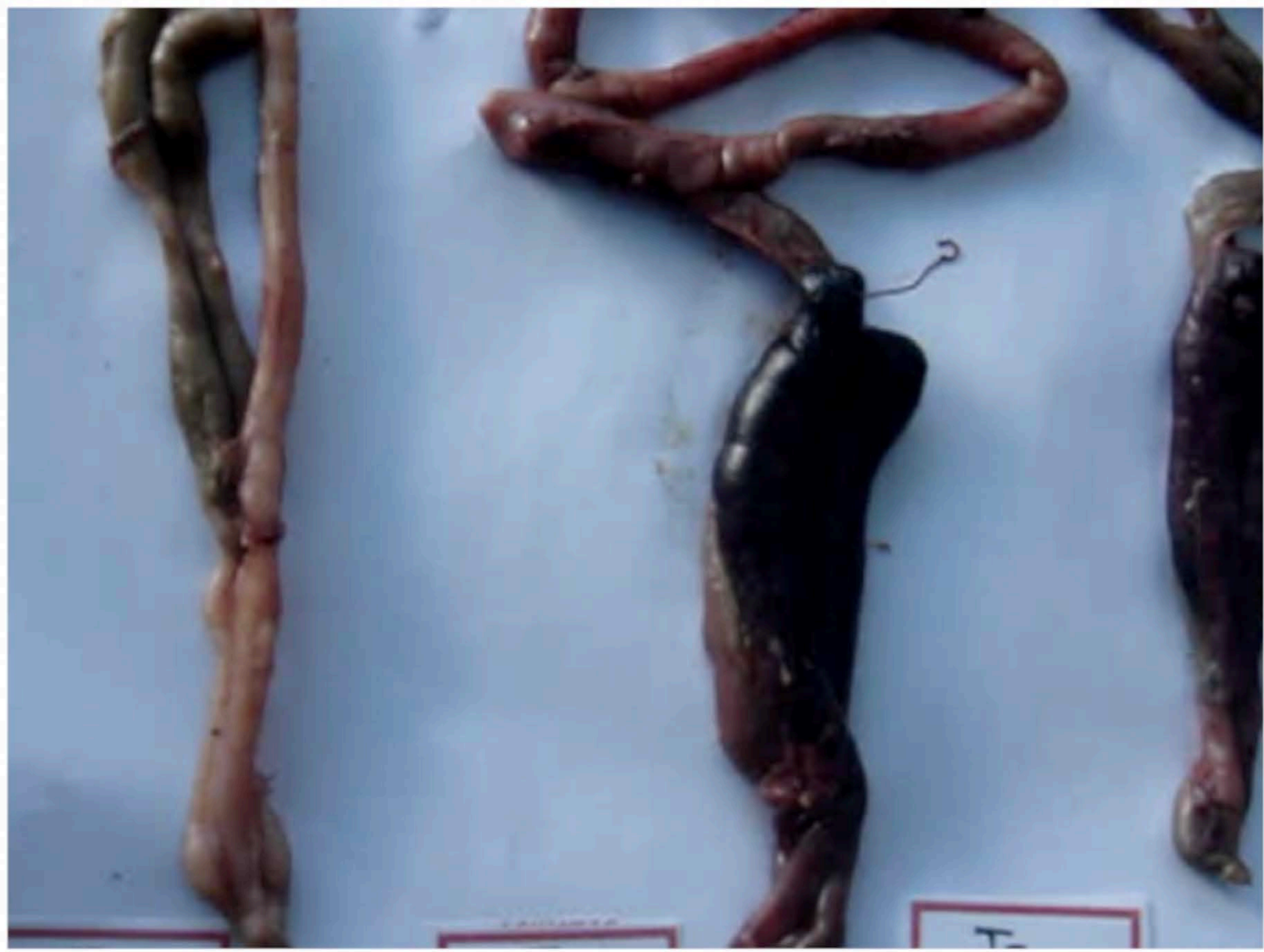# GROSS LESION SCORING TECHNIQUE



Score	Description
0	Normal
1	Minimal
2	Mild
3	Moderate
4	Severe



# GROSS LESION SCORING TECHNIQUE





# LESION SCORE CARD

## *E. necatrix*

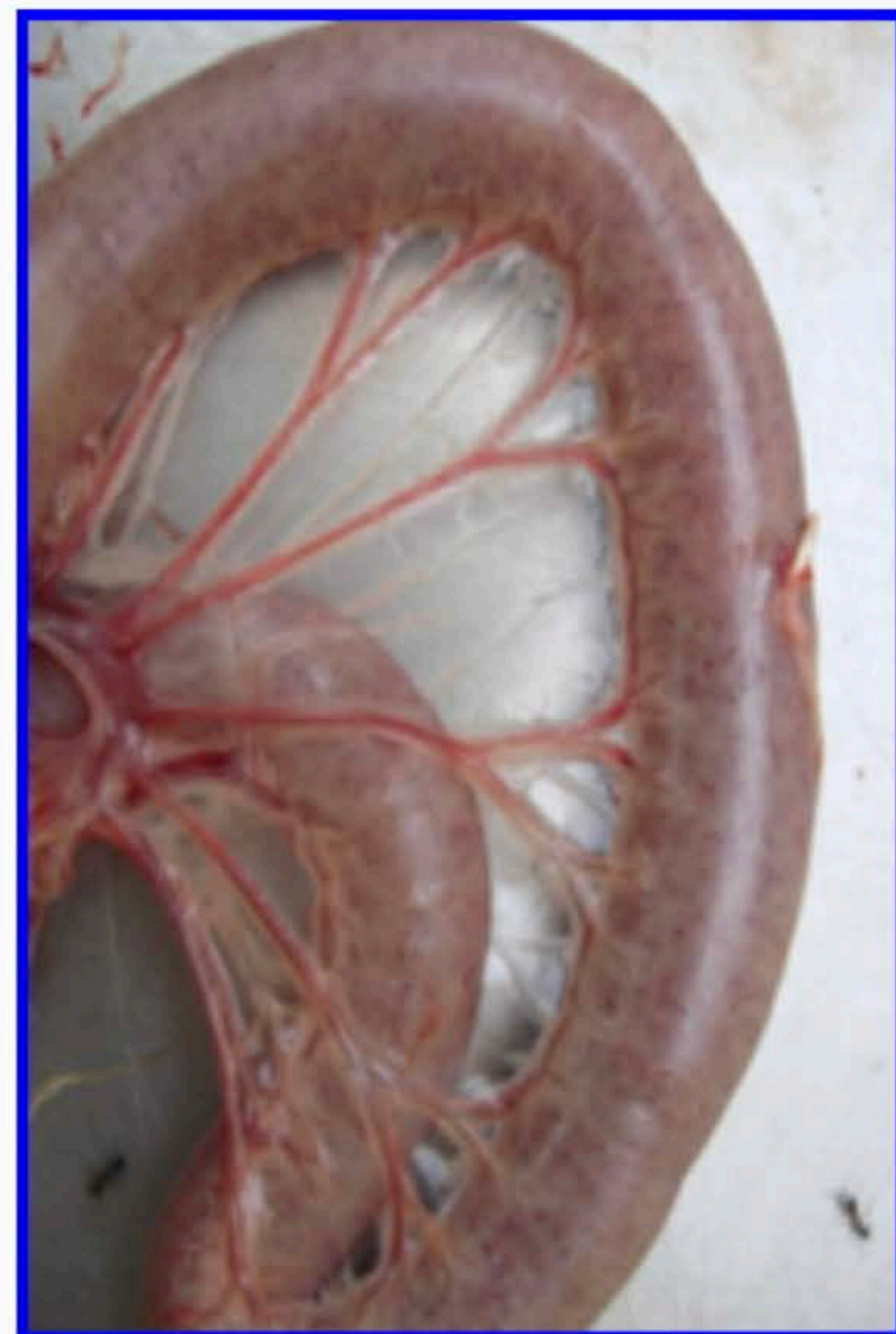
Lesions	Scoring 1	Scoring 2	Scoring 3	Scoring 4 (dead birds)
Gross Appearance	scattered petechiae, white patches on serosa	numerous petechiae on serosa, violent red.	extensive red petechiae, and white plaques on serosa	dark colour, extensive haemorrhages
Number of lesions	scattered	numerous	numerous	coalescent
Condition of Intestinal wall	normal	swelling limited to central part	rough, thickened and swollen up to lower part	swelling over whole intestine
Intestinal contents	normal	normal	extensive haemorrhage, red or brown mucus	very dark red or brown mucus

# GROSS LESION SCORING TECHNIQUE

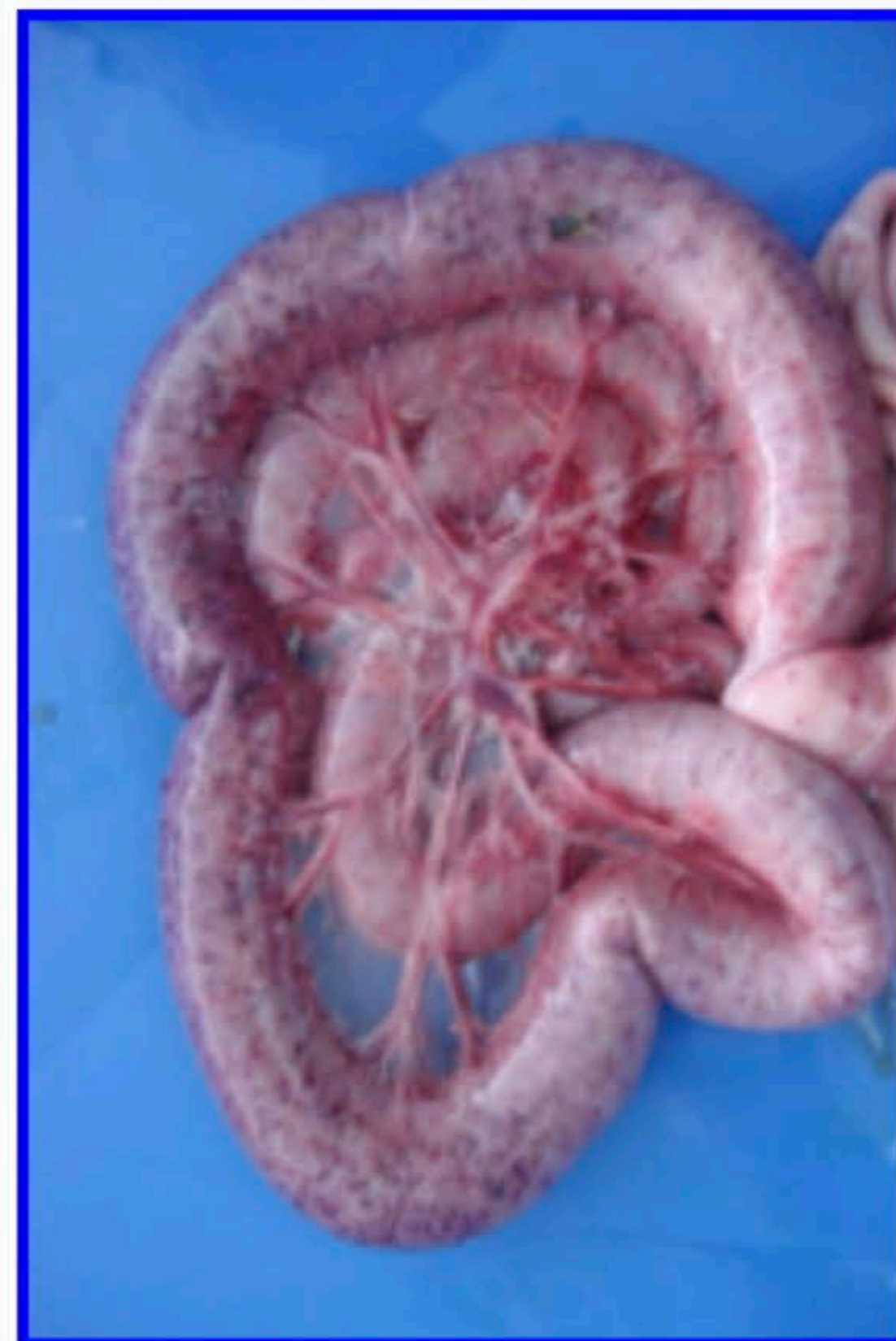## Midintestinal COCCIDIOSIS – *Eimeria necatrix*



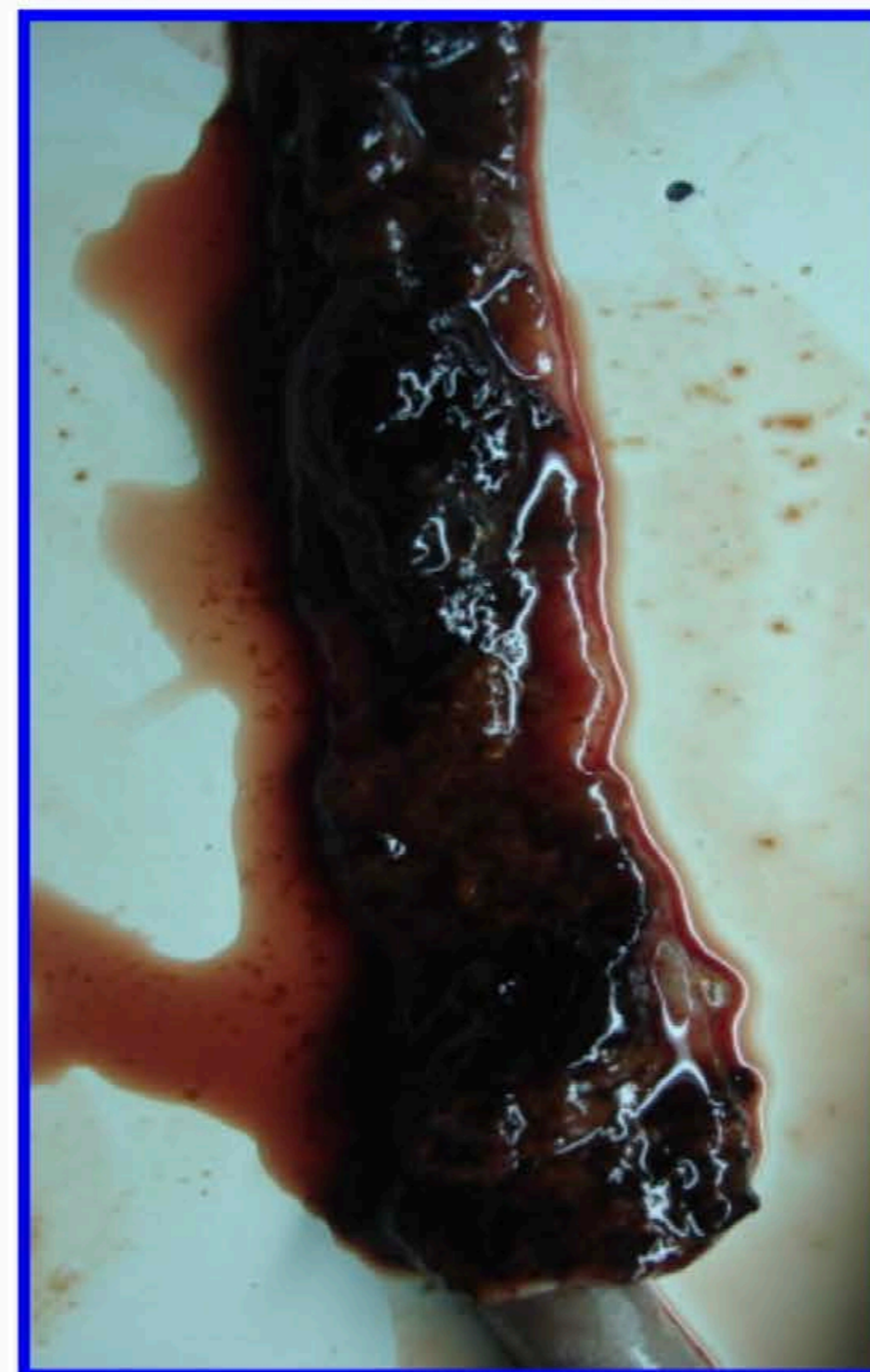Lesion Score 1



Lesion Score 2



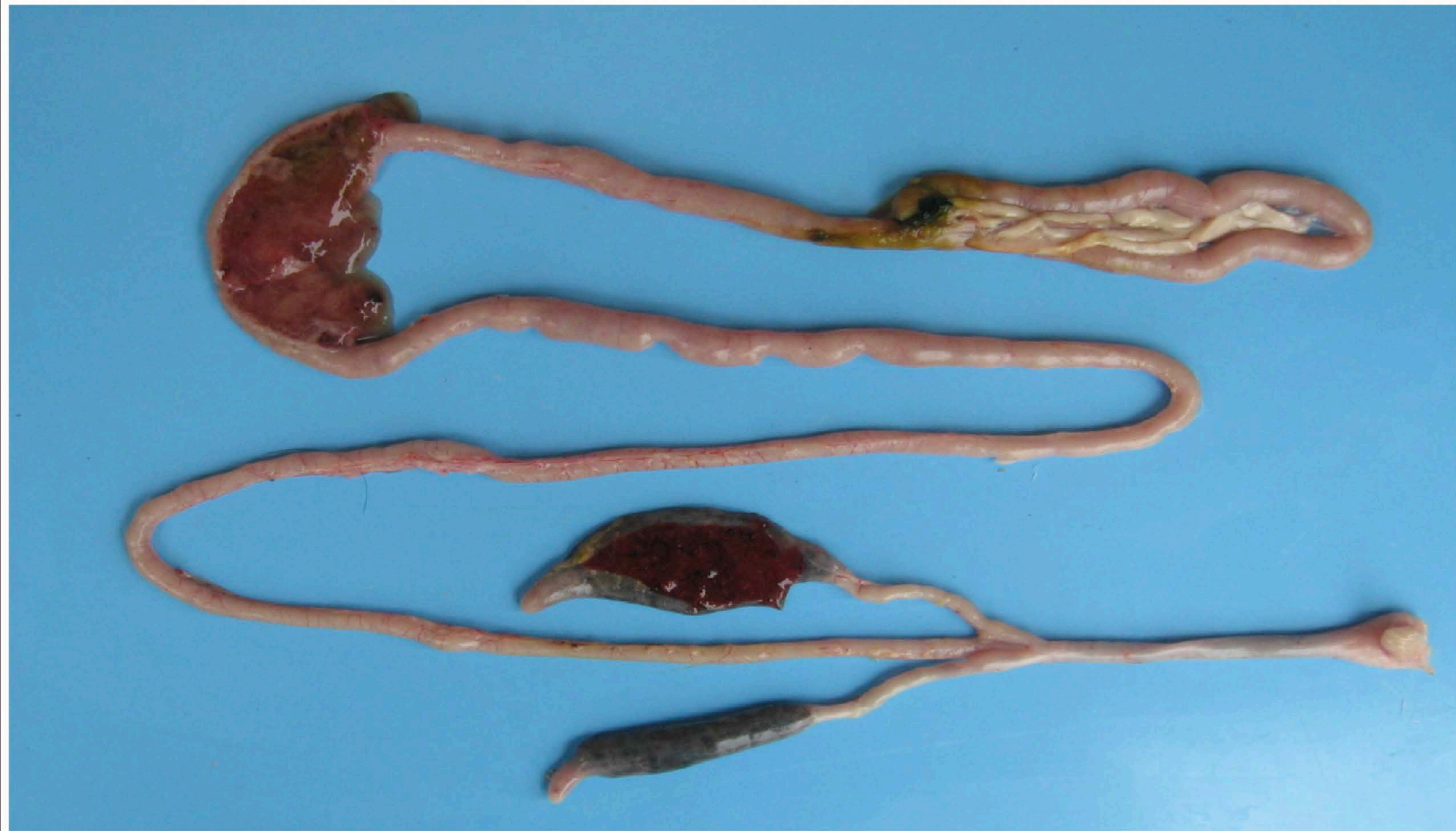
Lesion Score 3




Lesion Score 4



# GROSS LESION SCORING TECHNIQUE





# Lesion Scoring Chart for Chicken Coccidiosis (LESCHART)

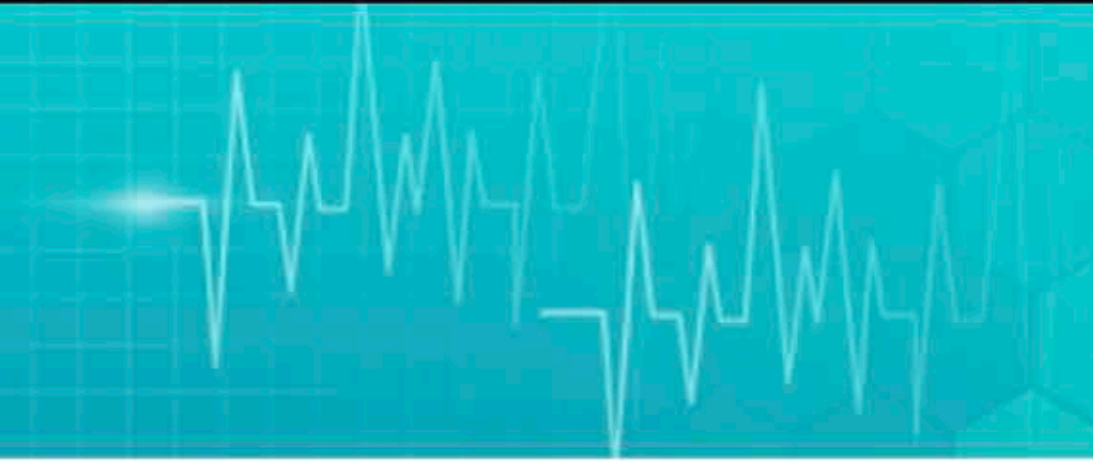Species	Location	Gross lesions observed in various stages of infection			
		Lesion score +1	Lesion score +2	Lesion score +3	Lesion score +4
<b><i>E. tenella</i></b>	<b>Caeca</b>	Few petechiae on the cecal wall with presence of normal contents	Mild ballooning with thickened cecal wall and bloody contents at the proximal end	Moderate ballooning of caecal loops with caecal core	Complete ballooning and distension of caecum packed with caseous cores
<b><i>E. acervulina</i></b>	<b>Anterior intestine</b>	Scattered petechiae in the anterior intestine	Vast lesion up to end of the mid gut	Intestinal greyish coated gut containing watery contents	Entire mucosa appears bright red with typical ladder like lesions and filled with creamy exudates
<b><i>E. brunetti</i></b>	<b>Posterior intestine</b>	Stagnation of faecal contents with apparently looking intestine	Slightly greyish intestinal wall, thickening of lower intestine with flecks of salmon colour material sloughed off the intestine	Thickening of intestinal wall with blood tinged catarrhal exudates. Transverse red streaks visible in rectum	Severe lesions extending upto the middle intestine
<b><i>E. maxima</i></b>	<b>Mid intestine</b>	Minimum amount of orange slimy mucus present	Intestine filled with orange mucus and without ballooning	Thickening of intestinal wall with mucus	Ballooning of whole intestine, contents with putrid odor
<b><i>E. necatrix</i></b>	<b>Mid intestine</b>	Scattered petechiae, white spots on the serosa (salt and pepper appearance)	Ballooning of midgut	Pin point hemorrhage in serosa and ballooning upto the lower intestine	Massive hemorrhage with brownish mucus contents



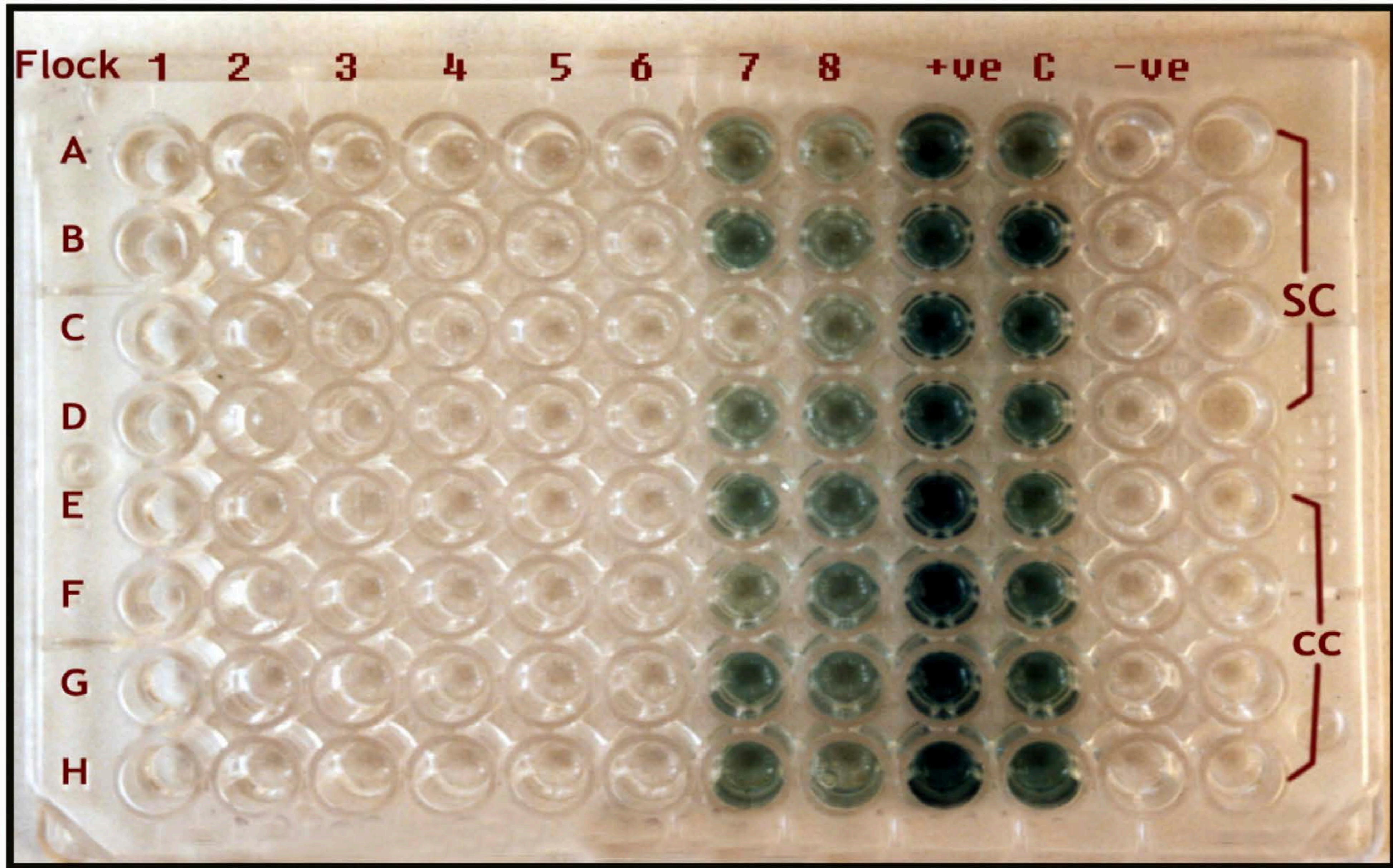


## IMMUNODIAGNOSIS

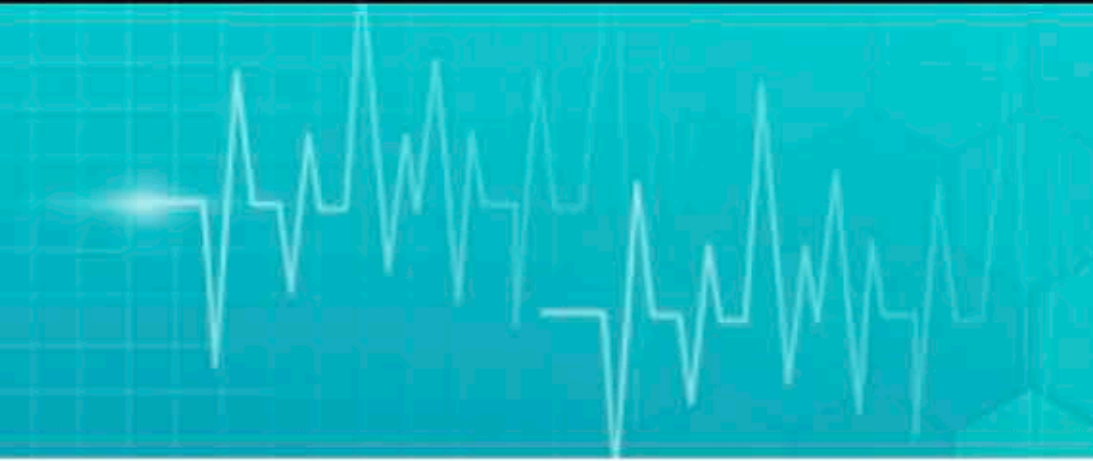- ▶ **Coproantigen detection ELISA, IHA and Dot-EIA**
- ▶ **Antibody detection ELISA and Dot-EIA**



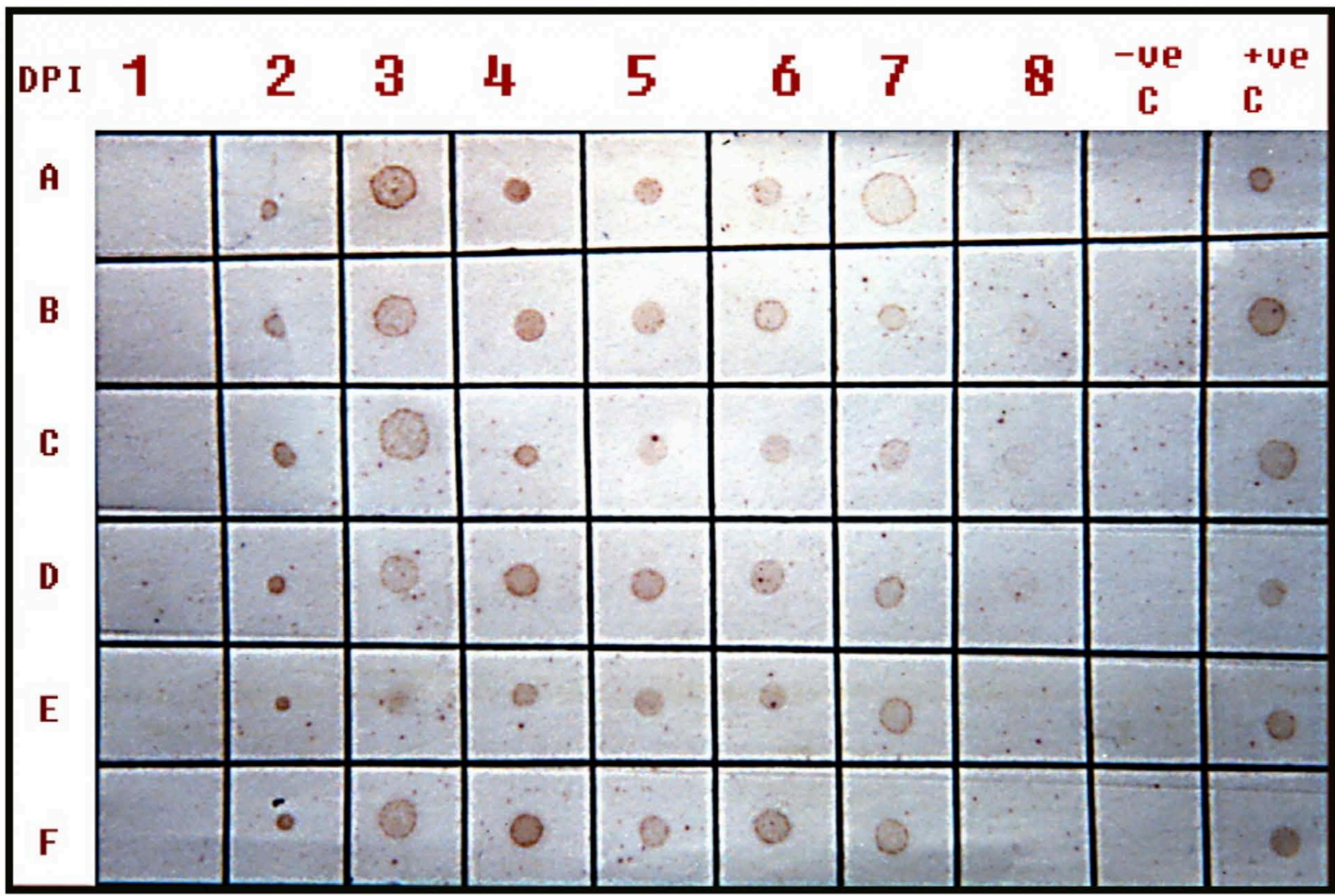
# Coproantigen detection by capture ELISA - experimental infection








# Coproantigen detection by Dot-EIA – experimental infection





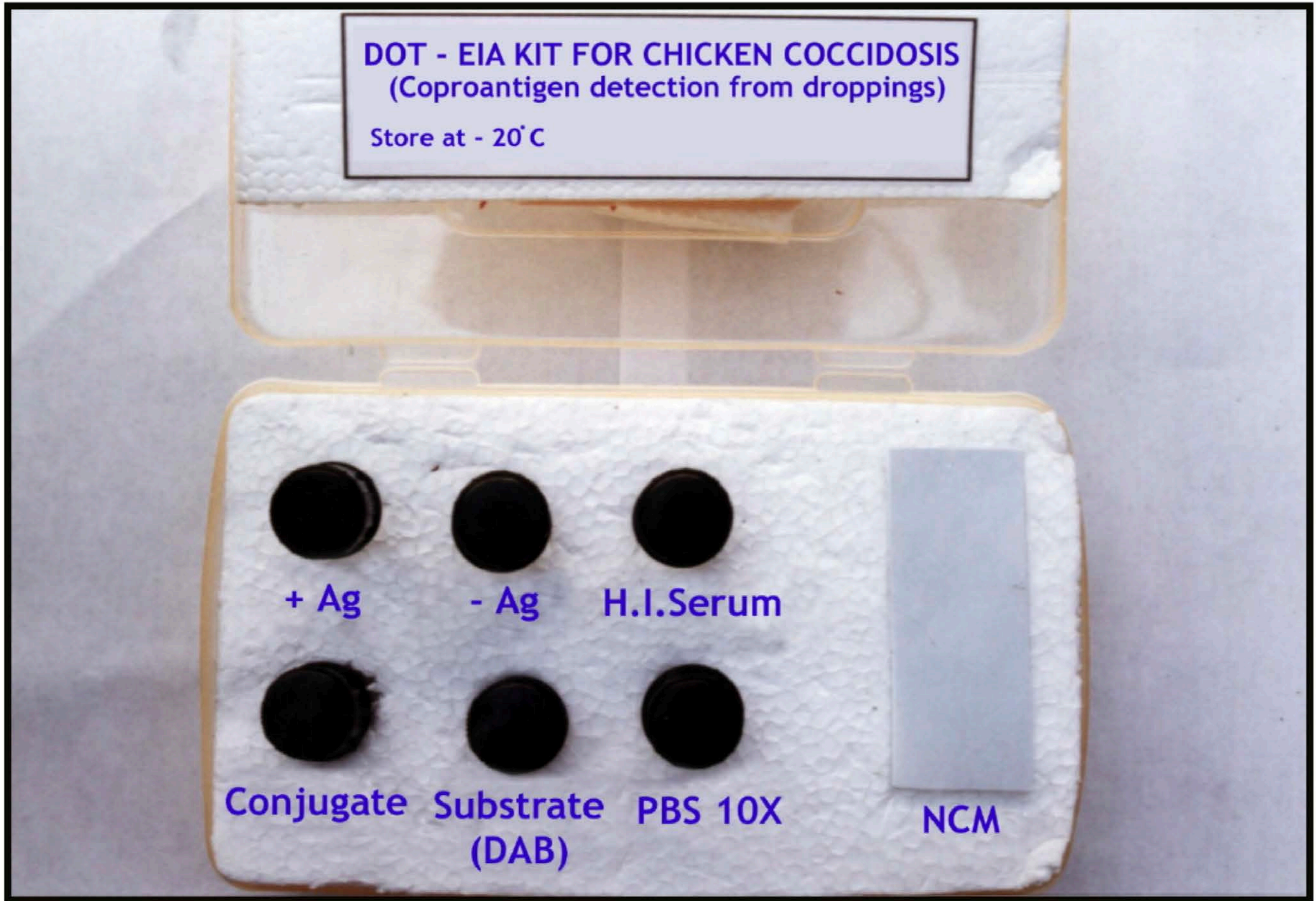# Coproantigen detection by Dot-EIA - field samples















































# Dot-EIA kit for caecal coccidiosis







# Antibody detection using Dot-EIA kit in breeder flocks

	1	2	3	4	5	6	7	8
	4 <sup>th</sup> Week	5 <sup>th</sup> Week	6 <sup>th</sup> Week	7 <sup>th</sup> Week	8 <sup>th</sup> Week	9 <sup>th</sup> Week	-- ve Control	+ ve Control
<b>A</b>								
<b>B</b>								
<b>C</b>								
<b>D</b>								
<b>E</b>								

3.3



## USEFULNESS OF THE DOT - EIA KIT

- ▶ **Early diagnosis of impending outbreak of caecal coccidiosis - before its prepatent period by coproantigen detection**
- ▶ **Easily adaptable to the field condition, portable and less time consuming especially when too many samples were examined**
- ▶ **Epidemiological survey**
- ▶ **Assessing the efficacy of treatment**
- ▶ **Assessing the efficacy of oral live vaccine**
- ▶ **Assessment of immune status of the flock (Antibody detection) against *E. tenella***


**BIOCHEMICAL AND  
MOLECULAR TECHNIQUES  
FOR IDENTIFICATION OF  
*EIMERIA* SPECIES AND  
STRAIN**



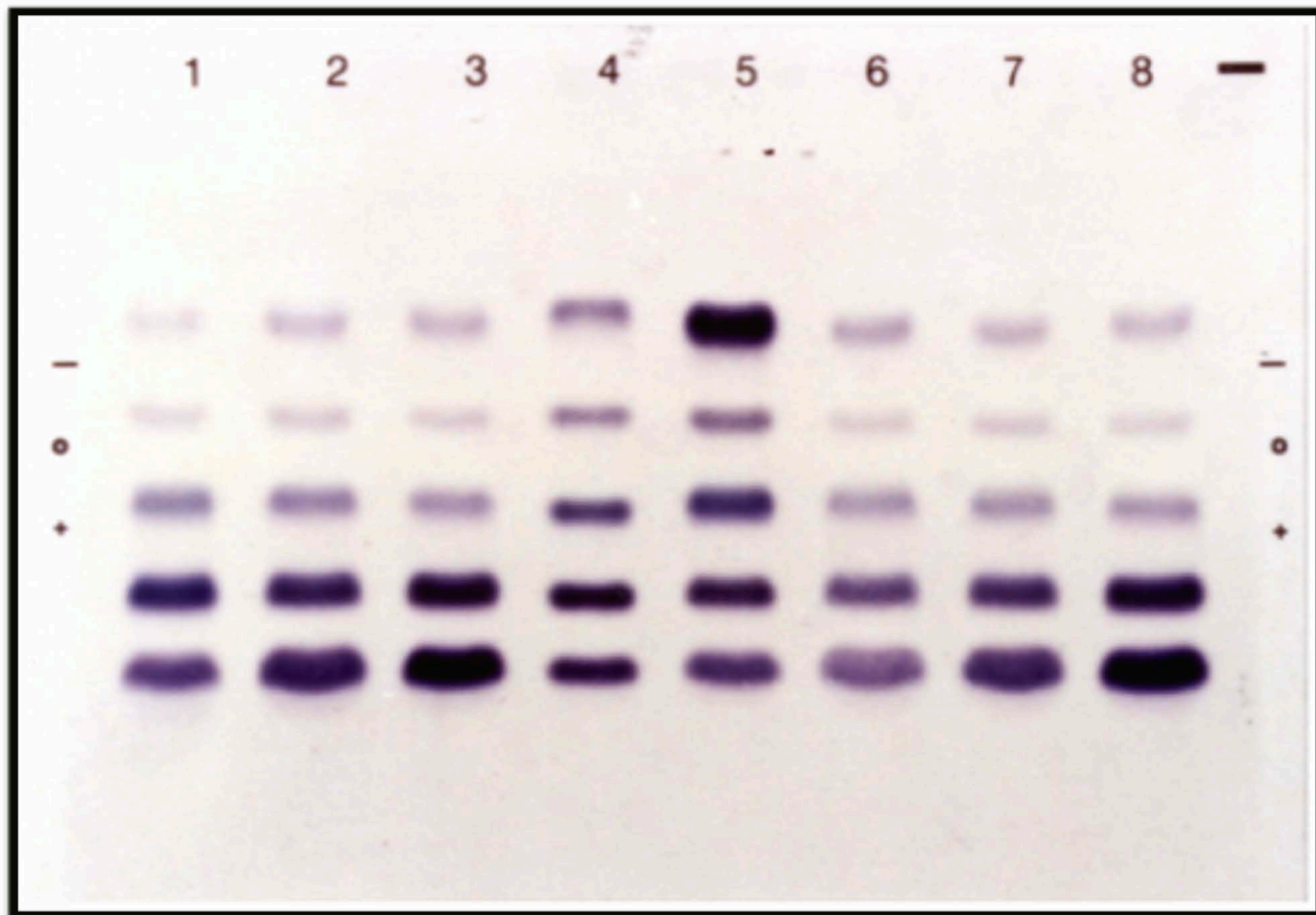


# BIOCHEMICAL AND MOLECULAR TECHNIQUES

- ▶ **Isoenzyme electrophoresis**
- ▶ **Electrophoretic protein characterisation**
- ▶ **DNA analyses**
- ▶ **RNA analyses**



# Isoenzyme LDH in *Eimeria*





## Recent Techniques

- ▶ **Pulse field gel electrophoresis for chromosomal characterization**
- ▶ **Restriction enzyme digestion and southern blotting**
- ▶ **5S ribosomal RNA characterization**
- ▶ **Polymerase chain reaction (PCR)**
- ▶ **Random amplified polymorphic DNA (RAPD) analysis**

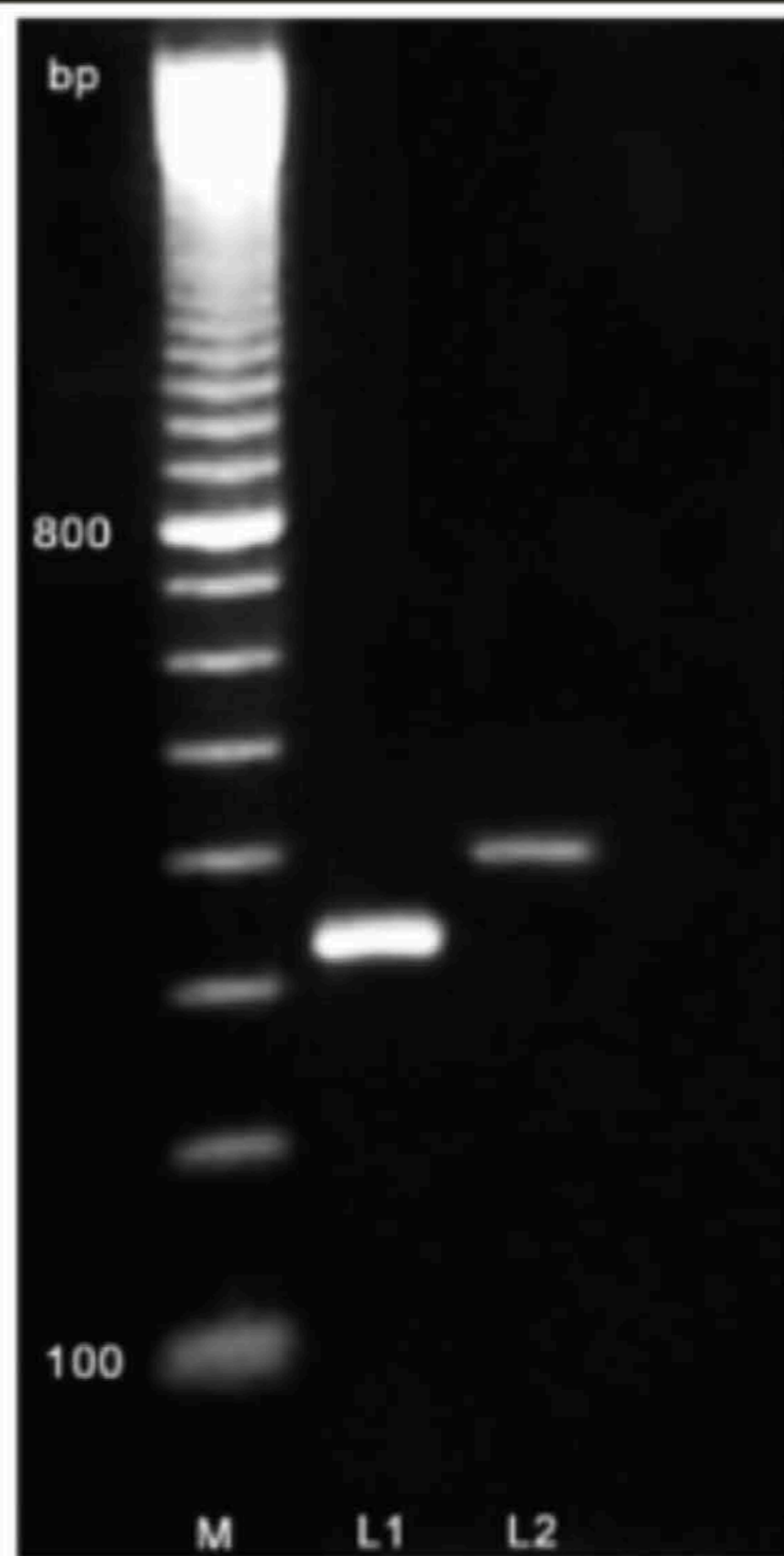


## Polymerase Chain Reaction (PCR)

- ▶ PCR makes it possible to identify specific DNA sequences from very small amounts of material.
- ▶ DNA can be prepared from various lifecycle forms such as,
  - ▶ Oocysts
  - ▶ Sporozoite
  - ▶ Merozoites
  - ▶ Gametocytes



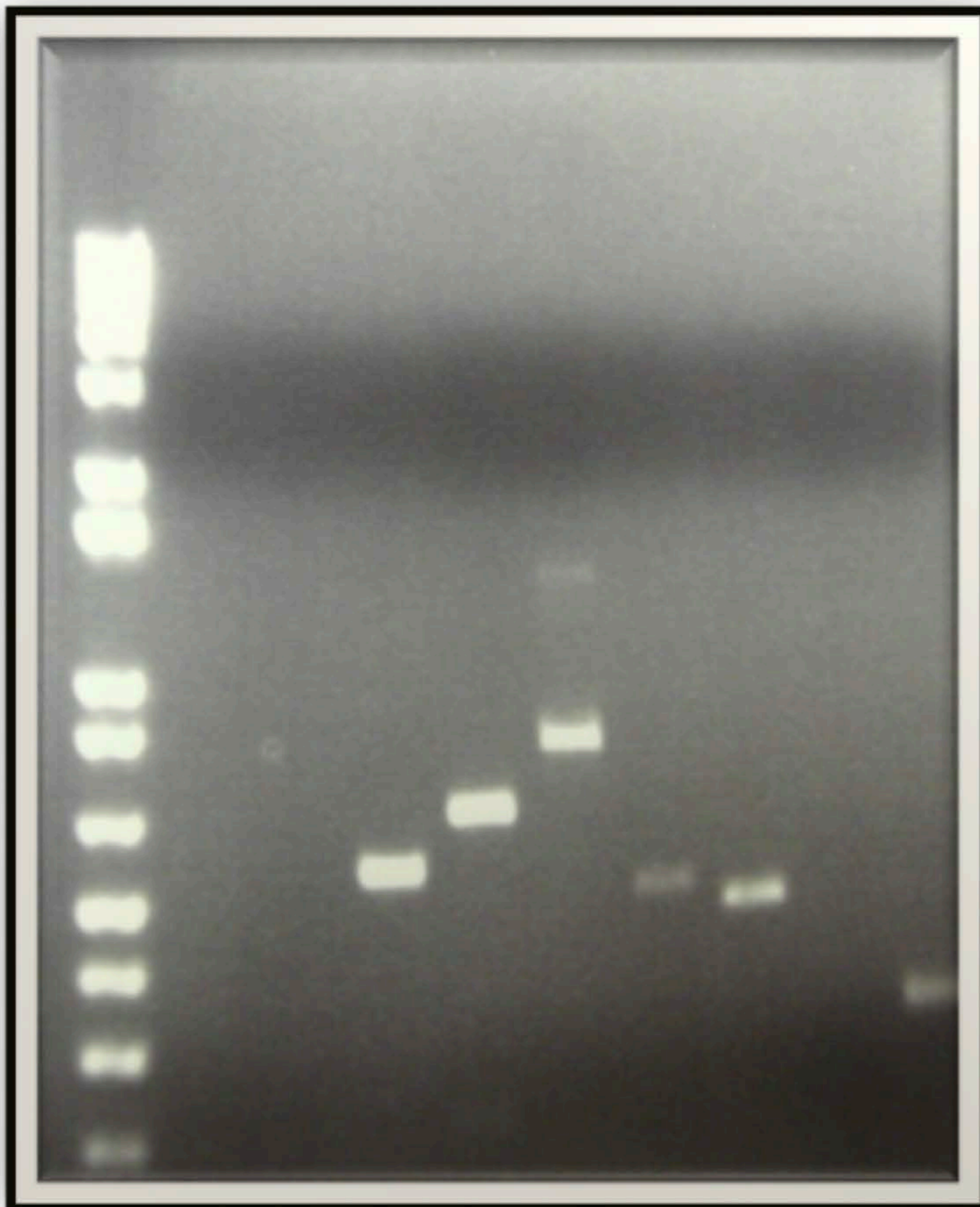
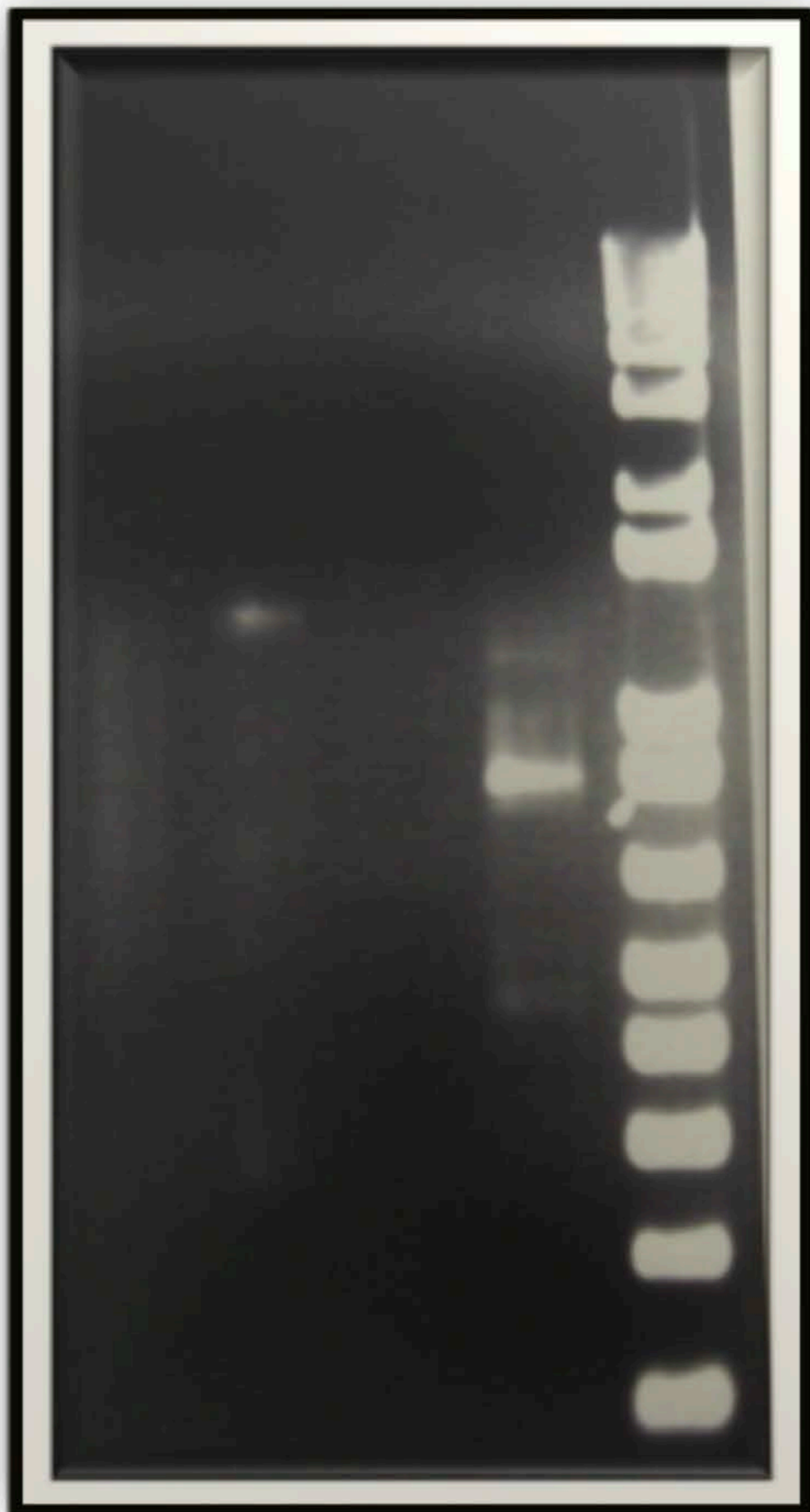# (PCR)



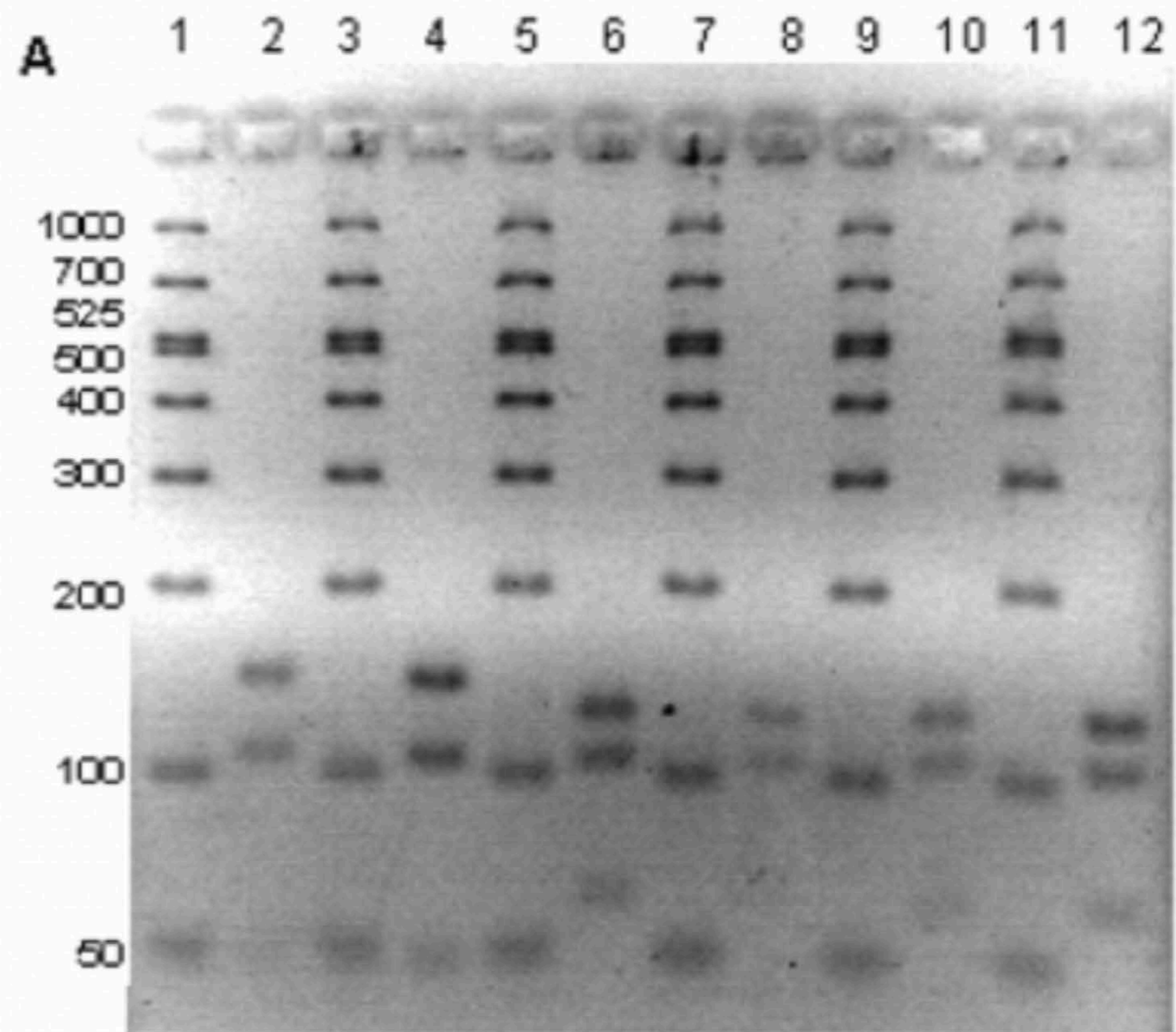
**Figure 1** - Agarose gel electrophoresis. Polymerase Chain Reaction for *E. mitis* and *E. praecox*. M: 100 bp molecular weight marker; L1: Positive sample for *E. mitis* (327 bp). L2: Positive sample for *E. praecox* (291 bp)



# Polymerase Chain Reaction

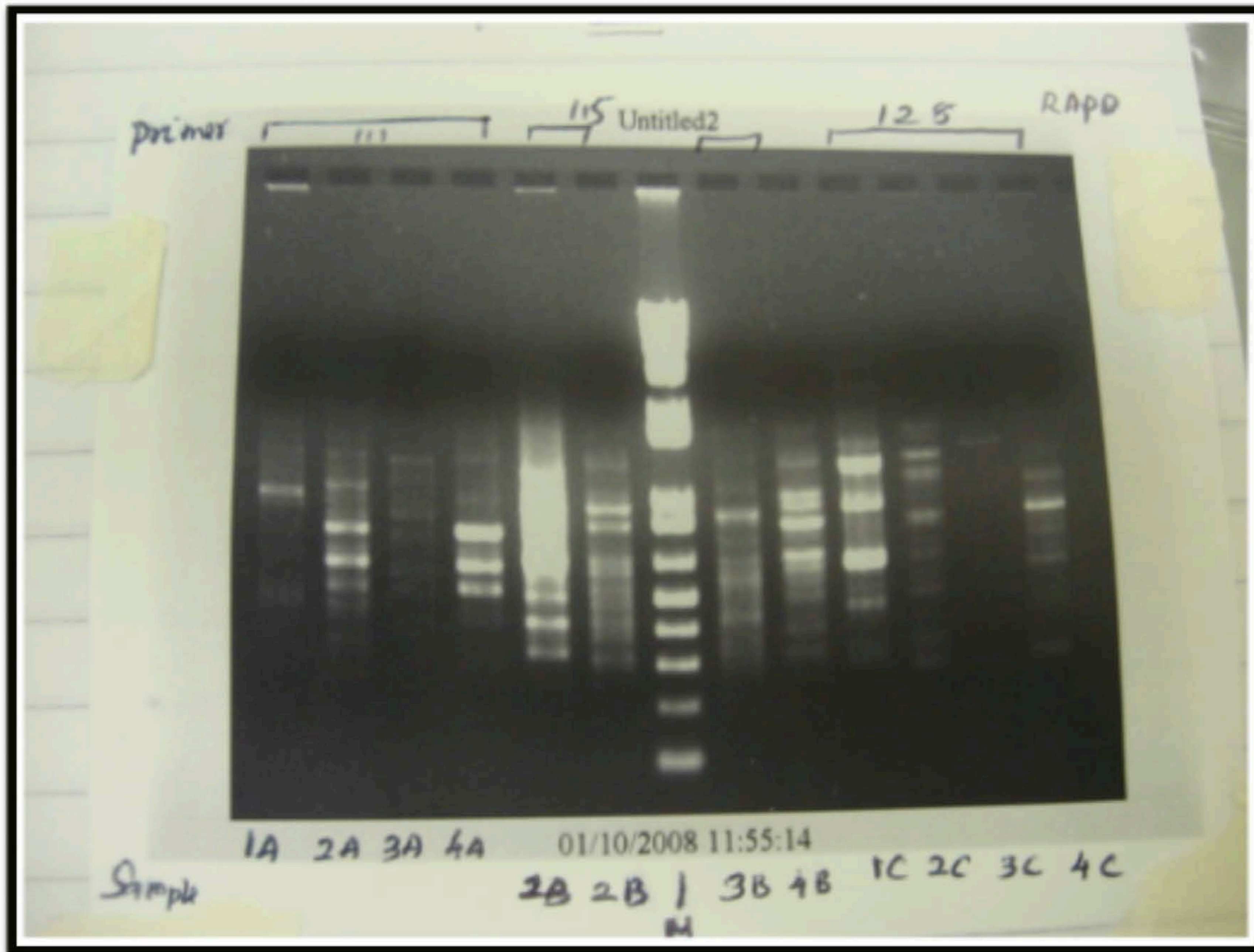


# RFLP





# PCR-RAPD analysis







## Summary of diagnosis of cocci

### Factors help in assessment of status of coccidiosis

- ▶ Combining autopsy findings with Nature of lesions
- ▶ Microscopic examination of contents, mucosal scrapings
- ▶ Observation on litter &
- ▶ Data found in records, Flock health and behaviour
- ▶ Our aim is judicious control, Not eradication of coccidiosis which is ideal for profitable chicken rearing



# CONCLUSION

## Trends in the diagnosis and control of chicken coccidiosis

### Recent techniques for diagnosis of chicken coccidiosis

**Estimation of litter oocyst density (OPG)**

***In-vitro* Sporulation of coccidia**

**Lesion Scoring Technique (GLS/MLS)**

**Immunodiagnosis of chicken coccidiosis**

**Biochemical and Molecular detection of coccidiosis**



*Thank you*